

## Role of nanofat injection in treating post-traumatic scars

Mahmoud A. Rageh<sup>1\*</sup> M.Sc, Mohamed El-Khalawany<sup>1</sup> MD, Shady Mahmoud Ibrahim<sup>1</sup> MD.

### \* Corresponding Author:

Mahmoud A. Rageh

[dr.mahmoudrageh@gmail.com](mailto:dr.mahmoudrageh@gmail.com)

Received for publication June 20,

2020; Accepted July 23, 2021;

Published online July 23, 2021.

**Copyright** The Authors published by Al-Azhar University, Faculty of Medicine, Cairo, Egypt. Users have the right to read, download, copy, distribute, print, search, or link to the full texts of articles under the following conditions: Creative Commons Attribution-Share Alike 4.0 International Public License (CC BY-SA 4.0)..

**doi:** 10.21608/aimj.2021.81579.1507.

<sup>1</sup>Dermatology Department, Faculty of Medicine, Al-Azhar University, Cairo, Egypt.

### ABSTRACT

**Background:** Scars are the common and unpleasing result that occur following injuries of different causes. They have a great impact on the affected subjects both physically and psychologically.

**Aim of the study:** to evaluate the role of autologous nanofat injection in refining the esthetic appearance of post-traumatic scars, along with pathological correlation of the results.

**Patients and Methods:** Nineteen patients with post-traumatic scars were treated with a single session of nanofat injection. The results were assessed after 6 months from the session using Vancouver scar scale (VSS) in addition to pathological evaluation via image analyzing system.

**Results:** The age ranged between 19 and 40 years old. Statistical significant improvement on the VSS was noted regarding the height and pigmentation of the treated scars. On histopathological evaluation, there was a high statistical significant increase regarding epidermal thickness, collagen fibers, elastic fibers, and vascularity.

**Conclusion:** Nanofat injection is a potential efficient therapeutic modality for post-traumatic scars.

**Keywords:** nanofat; fat grafting; scars; scar treatment.

**Disclosure:** The authors have no financial interest to declare in relation to the content of this article. The Article Processing Charge was paid for by the authors.

**Research Support:** RCT approval numbers: NCT04656067 and PACTR202101794541918

**Authorship:** All authors have a substantial contribution to the article.

### INTRODUCTION

Scars represent a fibrous tissue that replaces normal tissue following wounds, injuries, and some diseases. Scars are mostly benign in nature; however, they are able to cause major esthetic, functional, and social problems.<sup>1</sup>

Numerous modalities have been tried for treatment of scars, yet most of them were unsatisfactory. The quest for a safe and effective approach for treatment with good esthetic outcome is still a major concern.<sup>2</sup>

Neuber first described autologous fat grafting (AFG) in 1893 and it was further recognized by Coleman. In addition to its known filling effect, AFG is considered a potential mechanism for treating scars owing to the presence of adipose tissue derived stem cells (ADSCs) which have a high regenerative ability and can repair injured tissues.<sup>3,4</sup>

### PATIENTS AND METHODS

This is a prospective study that was conducted at Dermatology Department, Al-Azhar University. The study was approved by the Ethical Committee of Al-Azhar Faculty of Medicine.

The study included 19 patients with post-traumatic scars. Patients were recruited from the dermatology outpatient clinics of the university hospitals.

Informed written consents were signed by all participants of this study after explaining the nature of the study to them.

**Inclusion criterion:** all patients with post-traumatic scars including accidental and surgical traumas.

**Exclusion criteria:** age <18 or >50 years, recent scar injuries (<6 months), recent treatment of scars within the last month, bleeding disorders, contracted scars, hypertrophic scars, keloids, pregnancy, and lactation.

Scars were evaluated clinically by the Vancouver scar scale (VSS). The VSS score ranges between 0 – 14 evaluating vascularity, height, pliability, and pigmentation.<sup>5</sup>

We followed Coleman's<sup>6</sup> technique for AFG. Klein's<sup>7</sup> solution was used for tumescent anesthesia, then harvesting of fat (mostly from the abdomen) was done by negative pressure through a multi-port blunt tipped harvesting cannula attached to 10 ml syringe. Centrifugation of fat at 3000 rpm for 3 minutes was done to separate it from remnants of tumescent anesthesia and blood. Mechanical emulsification was then done via 30 passes using 1 mm connector mounted between two syringes. Fat was then passed through 400 µm filter to obtain the nanofat. Under complete aseptic conditions, intradermal nanofat injections were performed by 1

ml insulin syringes. Follow up was done one week after the procedure and then after 6 months.

Biopsy was taken (using a 2-mm punch) before the procedure and another biopsy was taken after 6 months to evaluate the response. Multiple stains were used including hematoxylin and eosin (H&E), Masson trichrome, orcein, CD-31, and S100. Objective evaluation was done by Leica Q500 MC image analyzing system from 5 random fields.

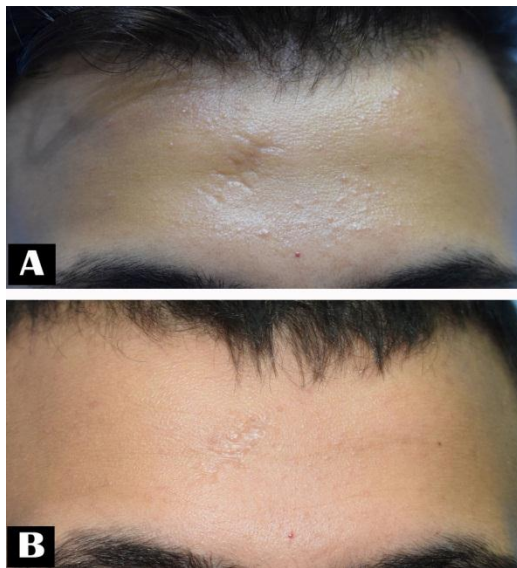
Statistical analysis was done using Statistical Package for Social Science (SPSS), Version 24.0.

## RESULTS

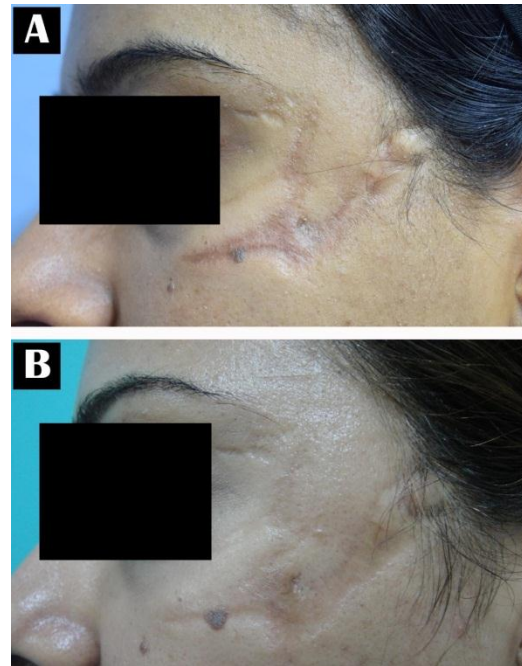
Nineteen patients were included, 10 (52.6%) females and 9 (47.4%) males. The age ranged between 19 - 40 years (mean  $\pm$  SD = 30.05  $\pm$  6.42). The duration of scars ranged from 2 to 11 years (4.53  $\pm$  2.55).

Face was the site of injury in 18 patients (94.7%) and 1 patient (5.3%) was affected in the abdomen.

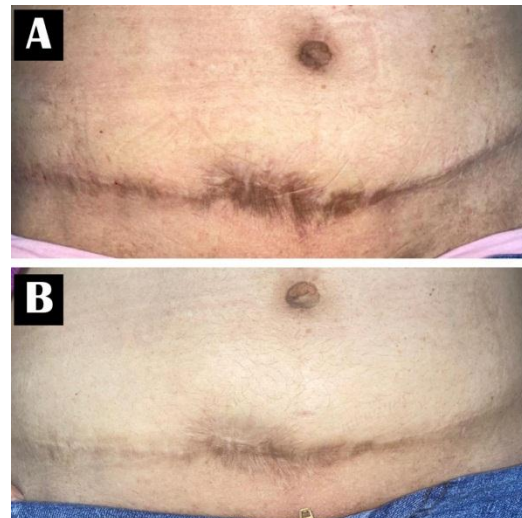Total VSS score showed a high statistical significant difference before and after treatment due to the high statistical significant difference in height, and the statistical significant difference in pigmentation (Figs. 1-3) (Table 1).



**Fig. 1:** Male patient 26 years old with post-traumatic scar of 9 years duration in the forehead. (A) Before treatment. (B) Six months after nanofat injection, marked improvement in height and pliability was seen and felt.



**Fig. 2:** Female patient 22 years old with post-traumatic scar of 6 years duration in the left zygomatic and temporal area. (A) Before treatment. (B) Six months after nanofat injection, improvement in height and pigmentation was noted with improved pliability.



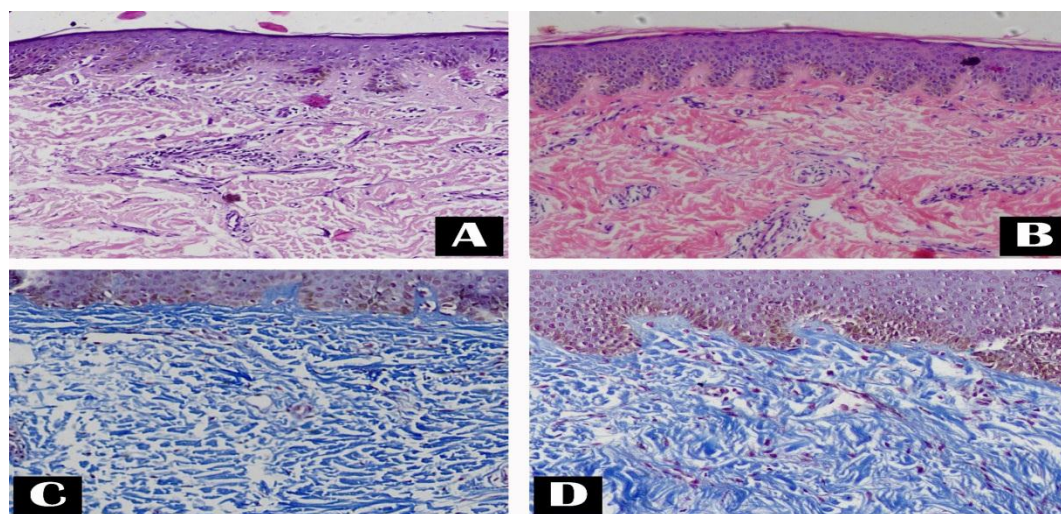
**Fig. 3:** Female patient 29 years old with post-surgical abdominal scar of 2 years duration. (A) Before treatment. (B) Six months after nanofat injection, marked improvement in color and texture was seen.

		Before (N = 19)		After (N = 19)		Stat test	P-value
Vascularity	Normal	18	94.7%	16	84.2%	X <sup>2</sup> = 2.11	0.347 NS
	Pink	1	5.3%	1	5.3%		
	Red	0	0%	2	10.5%		
Pigmentation	Normal	13	68.4%	10	52.6%	X <sup>2</sup> = 9.2	0.027 S
	Hypo	3	15.8%	0	0%		
	Mixed	2	10.5%	1	5.3%		
	Hyper	1	5.3%	8	42.1%		
Pliability	Normal	2	10.5%	0	0%	X <sup>2</sup> = 6.3	0.097 NS
	Supple	16	84.2%	13	68.4%		
	Yielding	1	5.3%	3	15.8%		
	Firm	0	0%	3	15.8%		
Height	Flat	8	42.1%	0	0%	X <sup>2</sup> = 22.5	< 0.001 HS
	< 2mm	11	57.9%	6	31.6%		
	2-5 mm	0	0%	13	68.4%		
Total VSS	Median	2		5		MW = 44	< 0.001 HS
	IQR	1 - 3		3 - 6			

X2: Chi-square test; MW: Mann-Whitney test; NS: p-value > 0.05 is considered non-significant; S: p-value < 0.05 is considered significant; HS: p-value < 0.001 is considered highly significant.

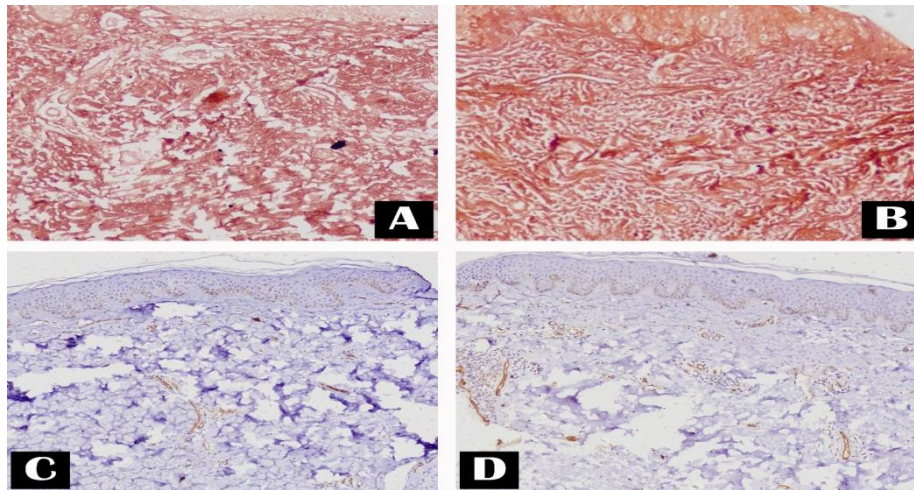
**Table 1:** Comparison of VSS before and after nanofat injection:

Pathological assessment showed high statistical significant improvement of epidermal thickness, collagen and elastic fibers thickness, and new blood vessels formation. Despite melanocytes exhibited normalized distribution in some patients, no statistical significant difference was recorded (Fig. 4-5) (Table 2).



**Fig. 4:** (A) Before treatment (H&E x100); nearly flattened epidermis. (B) Six months after nanofat, revealing increased epidermal thickness, rete-ridges elongation with undulating dermoepidermal junction (H&E x100). (C) Before treatment (Masson trichrome x100); random distribution of collagen fibers with increased inter-fibrillar spaces. (D) Six months after nanofat, revealing increased collagen density, decreased interfibrillar spaces (Masson trichrome x100).





**Fig. 5:** (A) Before treatment (orcein x100); decreased density of elastic fibers. (B) Six months after nanofat, showing increased density of elastic fibers (orcein x100). (C) Before treatment (CD-31 x100); randomly distributed vascular spaces. (D) Six months after nanofat, showing increased angiogenesis (CD-31 x100).

		Before (N = 19)	After (N = 19)	T	P-value
Epidermal thickness (µm)	Mean	62.2	96.4	4.3	< 0.001 HS
	±SD	6.5	34.0		
Collagen fibers thickness (Area %)	Mean	32.2	49.8	7.1	< 0.001 HS
	±SD	7.5	7.8		
Elastic fibers thickness (Area %)	Mean	36.1	52.4	5.7	< 0.001 HS
	±SD	8.9	8.7		
Vascularity (Area %)	Mean	0.8	1.4	3.8	< 0.001 HS
	±SD	0.4	0.6		
Pigmentation (Optical density)	Mean	76.6	73.3	1.22	0.230 NS
	±SD	8.6	7.7		

IQR: Interquartile Range; T: Independent sample T test.

**Table 2:** Comparison of pathological findings before and after nanofat injection.

Regarding procedural pain, 13 patients (68.4%) reported mild pain, 4 patients (21.1%) reported moderate pain. Bruising occurred in 4 patients (21.1%), erythema in 2 patients (10.5%), edema in 1 patient (5.3%), and hyperpigmentation in 1 patient (5.3%), while 11 patients (57.9%) experienced no complications.

One patient (5.3%) reported slight improvement, 2 patients (10.5%) reported moderate improvement, 6 patients (31.6%) reported significant improvement and 10 patients (52.6%) reported marked improvement after evaluating patients' satisfaction.

## DISCUSSION

Fat grafting has emerged as a credible solution for the reconstructive treatment of scars. Prior studies have hypothesized that ADSCs contribute to wound healing by inducing new blood vessels formation and releasing growth factors that help reduce inflammation and fibrosis. ADSCs resemble “seeds” which can recultivate their environment with new cells inducing tissue regeneration.<sup>10</sup>

The mechanical procedure of emulsifying and filtration of fat to obtain “nanofat” was firstly recognized by Tonnard et al in 2013. Nanofat is considered a substantial source of ADSCs which can promote wound healing and help in tissue reconstruction through release of growth factors.<sup>11</sup>

All treated scars in our study were mature (>2 years), eliminating the role of physiologic healing in the results. Most patients were treated from facial scars. This shows that the social impact of facial scars is a major motivating factor for patients to seek treatment.

ADSCs within nanofat help in stimulating collagen and elastic tissue deposition leading to improvement in scar pliability in addition to the filling effect of fat itself that improves the height of the treated scars.<sup>12</sup>

The results of our study comes in agreement with Lee et al<sup>13</sup> who recorded significant improvement on VSS after simultaneous fat injection with surgical scar reduction.

Jaspers et al<sup>14</sup> used a cutometer and documented significant improvements in overall Patient Observer Scar Assessment Scale (POSAS) over a 3-months follow-up period after fat grafting.

In a study by Pallua and Kim,<sup>15</sup> they investigated the outcome of facial scars treated with AFG. The POSAS scores significantly improved regarding pain, color, stiffness, irregularity, pigmentation, and pliability.

Similarly, Bollero et al<sup>16</sup> treated 19 patients who suffered from burn, traumatic and surgical scars with AFG. Their results showed improved scar quality with restored contouring.

A systematic review by Riyat et al<sup>17</sup> assessed the efficiency of AFG in scar treatment. Assessment was done for 1158 patients regarding the scars color, thickness, volume, and restored functions after treatment. All parameters exhibited positive outcome.

Our results also agrees with Jan et al<sup>12</sup> and Gu et al.<sup>18</sup> Both studies noticed significant improvement in scar pigmentation after using nanofat for post-burn and atrophic facial scars. Nanofat could have a whitening effect on scars through inhibiting tyrosinase enzyme and synthesis of melanin.<sup>19</sup>

Conversely, Brown et al<sup>20</sup> compared the effects of fat versus saline in treatment of scars. Results demonstrated that AFG can improve the qualitative

profile of a scar. However, there was no difference noted when compared to saline.

Fat grafting induced organization of deposited collagen, angiogenesis, and dermal reconstitution. This comes in agreement with our pathological results.<sup>21-24</sup>

Mojallal et al<sup>25</sup> demonstrated neosynthesis of collagen fibers and subsequent dermal thickening in a nude murine model after subdermal injection of human fat tissue.

Contrary to our results, Brown et al<sup>20</sup> compared the effects of fat versus saline in treatment of scars. There were no significant differences histologically between fat and saline-treated areas regarding vascularity, inflammation, and epidermal thickness.

The pathological changes could be owed to the presence of ADSCs within nanofat which are able to stimulate hyperplasia of epithelium and induce new blood vessels formation.<sup>26</sup> The heterogeneous multipotent stem cells within the ADSCs can transform into the host cell lineage such as adipogenic, chondrogenic, cardiogenic, and neurogenic.<sup>12, 27</sup>

## CONCLUSION

Autologous nanofat injection for treating post-traumatic scars resulted in a significant improvement from both clinical and pathological perspectives. However, long term Follow-up of patients after treatment is recommended in order to clearly document the longevity of nanofat and to evaluate the final outcomes of its efficacy. Our results should be encouraging for further studies regarding the use of nanofat in treating various types of scars including the availability of combined therapy using nanofat with other modalities as fractional CO<sub>2</sub> laser and/or platelet-rich plasma to evaluate their synergistic effect in treatment of the scar tissue.

## REFERENCES

1. Keen A, Sheikh G, Hassan I, Jabeen Y, Rather S, et al. Treatment of post-burn and post-traumatic atrophic scars with fractional CO<sub>2</sub> laser: experience at a tertiary care centre. *Lasers Med Sci.* 2018;33(5):1039-46.
2. Alster TS, Lupton JR. Lasers in dermatology. An overview of types and indications. *Am J Clin Dermatol.* 2001;2:291-303.
3. Klinger M, Klinger F, Caviggioli F, Maione L, Catania B, et al. Fat Grafting for Treatment of Facial Scars. *Clin Plast Surg.* 2020;47(1):131-8.
4. James IB, Coleman SR, Rubin JP. Fat, Stem Cells, and Platelet-Rich Plasma. *Clin Plast Surg.* 2016;43(3):473-88.
5. Fearmonti R, Bond J, Erdmann D, Levinson H. A review of scar scales and scar measuring devices. *Eplasty.* 2010;10:354-63.

6. Coleman SR. Structural fat grafting: more than a permanent filler. *Plast Reconstr Surg.* 2006;118(3 Suppl):108S-120S.
7. Klein JA. Tumescent technique for local anesthesia. *West J Med.* 1996;164:517.
8. Johnson C. Measuring pain. Visual analog scale versus numeric pain scale: what is the difference. *J Chiropr Med.* 2005;4(1):43-4.
9. Majid I, Imran S. Fractional CO2 laser resurfacing as monotherapy in the treatment of atrophic facial acne scars. *J Cutan Aesthet Surg.* 2014;7(2):87.
10. Gal S, Ramirez JI, Maguina P. Autologous fat grafting does not improve burn scar appearance: a prospective, randomized, double-blinded, placebo-controlled, pilot study. *Burns.* 2017;43:486-9.
11. Tonnard P, Verpaele A, Peeters G, Hamdi M, Cornelissen M, et al. Nanofat grafting: basic research and clinical applications. *Plast Reconstr Surg.* 2013;132(4):1017-26.
12. J an SN, Bashir MM, Khan FA, Hidayat Z, Ansari HH, et al. Unfiltered Nanofat Injections Rejuvenate Postburn Scars of Face. *Ann Plast Surg.* 2019;82(1):28-33.
13. Lee JW, Park SH, Lee SJ, Kim SH, Suh IS, et al. Clinical Impact of Highly Condensed Stromal Vascular Fraction Injection in Surgical Management of Depressed and Contracted Scars. *Aesthetic Plast Surg.* 2018;42(6):1689-98.
14. Jaspers MEH, Brouwer KM, van Trier AJM, Groot ML, Middelkoop E, et al. Effectiveness of autologous fat grafting in adherent scars: results obtained by a comprehensive scar evaluation protocol. *Plast Reconstr Surg.* 2017;139:212-9.
15. Pallua N, Kim BS. Microfat and Lipoconcentrate for the Treatment of Facial Scars. *Clin Plast Surg.* 2020;47(1):139-45.
16. Bollero D, Pozza S, Gangemi EN, De Marchi A, Ganem J, et al. Contrast-enhanced ultrasonography evaluation after autologous fat grafting in scar revision. *G Chir.* 2014;35(11-12):266-73.
17. Riyat H, Touil LL, Briggs M, Shokrollahi K. Autologous fat grafting for scars, healing and pain: a review. *Scars Burn Heal.* 2017;3 :2059513117728200.
18. Gu Z, Li Y, Li H. Use of Condensed Nanofat Combined With Fat Grafts to Treat Atrophic Scars. *JAMA Facial Plast Surg.* 2018;20(2):128-35.
19. Kim JH, Jung M, Kim HS, Kim YM, Choi EH. Adipose-derived stem cells as a new therapeutic modality for ageing skin. *Exp Dermatol.* 2011;20(5):383-7.
20. Brown JC, Shang H, Yang N, Pierson J, Ratliff CR, et al. Autologous Fat Transfer for Scar Prevention and Remodeling: A Randomized, Blinded, Placebo-controlled Trial. *Plast Reconstr Surg Glob Open.* 2020;8(5):e2830.
21. Klinger M, Marazzi M, Vigo D, Torre M. Fat injection for cases of severe burn outcomes: a new perspective of scar remodeling and reduction. *Aesthetic Plast Surg.* 2008;32(3):465-9.
22. Brongo S, Nicoletti GF, La Padula S, Mele CM, D'Andrea F. Use of lipofilling for the treatment of severe burn outcomes. *Plast Reconstr Surg.* 2012;130:374e-376e.
23. Deng C, Yao Y, Liu Z, Li H, Yang Z, et al. Chronic wound treatment with high-density nanofat grafting combined with negative pressure wound therapy. *Int J Clin Exp Med.* 2019;12(2):1402-11.
24. Bruno A, Delli Santi G, Fasciani L, Cempanari M, Palombo M, et al. Burn scar lipofilling: Immunohistochemical and clinical outcomes. *J Craniofac Surg.* 2013;24:1806-14.
25. Mojallal A, Lequeux C, Shipkov C, Breton P, Foyatier JL, et al. Improvement of skin quality after fat grafting: clinical observation and an animal study. *Plast Reconstr Surg.* 2009;124(3):765-74.
26. Klinger M, Caviggioli F, Klinger FM, Giannasi S, Bandi V, et al. Autologous fat graft in scar treatment. *J Craniofac Surg.* 2013;24(5):1610-5.
27. Tsuji W. Adipose-derived stem cells: Implications in tissue regeneration. *World J Stem Cells.* 2014;6(3):312.