

Lipofilling as an Adjuvant Therapy for Postburn Grafted Hand: Functional and Aesthetic Outcome

Plastic Surgery

Esraa Mohamed Fathy Metwaly¹ ; Magdy Ahmed Abd-El Mektader Abd-El Kareem¹ MD, Moustafa Sayed Ahmed Meki¹ MD.

*** Corresponding Author:**

Esraa Metwaly

esraa.mf888@gmail.com

Received for publication March 2, 2021; Accepted April 9, 2020; Published online April 10, 2020.

Copyright 2020 The Authors published by Al-Azhar University, Faculty of Medicine, Cairo, Egypt. All rights reserved. This an open-access article distributed under the legal terms, where it is permissible to download and share the work provided it is properly cited. The work cannot be changed in any way or used commercially.

doi: [10.21608/aimj.2021.63707.1421](https://doi.org/10.21608/aimj.2021.63707.1421)

¹ Department of Plastic and Reconstructive Surgery, Faculty of Medicine, AL-Azhar University, Cairo, Egypt.

Disclosure: The authors have no financial interest to declare in relation to the content of this article. The Article Processing Charge was paid for by the authors.
Authorship: All authors have a substantial contribution to the article.

INTRODUCTION

Handling severe burn damages of the hand is a challenge of considerable interest. Long-range risks as hypertrophic scar and retraction could lead to deformities, possible loss of functionality, and a negative impact on the life's quality.^{1,2}

ABSTRACT

Background :

Background: Fat transfer is widely used as an adjuvant therapy to achieve the deficiencies faced minor burning regeneration.

Aim of the study:

The study aimed to represent our experience with autologous fat grafting in improving hand function and cosmesis in cases that undergo skin grafts after burns to the hand dorsum.

Patient and methods:

A case series study where patients aged 16-60 with post-burn grafted hand contractures, evaluating functional and aesthetic outcomes after a single session of lipofilling; A case series study carried out from May 2019 to August 2020 on twenty patients with post-burn grafted hand contractures. All patients underwent autologous fat transfer to their burnt grafted hands. Hand function and cosmesis and Patients' contentment were evaluated utilizing the Patient Observer Scar Assessment Scale.

Results:

Follow after lipofilling showed general improvement of the burnt hand. Regarding the assessment of hand function, there was a statistical development throughout the total active movement. Regarding the assessment of patient satisfaction, there were significant improvements in pain, itching, scar color, volume, stiffness, skin softening (P-value<0.001 for all). Regarding the assessment of doctor opinion, vascularity, pigmentation, pliability, and pain relief were significantly improved (P-value<0.001)

Conclusion:

Lipofilling is an effective and safe adjuvant therapy to improve the hand's post-burn contractures and aesthetic appearance.

Key Words:

Burn; Hand; graft Lipofilling.

Treatment for post-burn, hypertrophic scar, and tightness includes different non-operative treatment like a mechanistic compressing bandage, a silicon sheet, steroid injection, and laser therapy. These are considered as the first line of option and even in integration with an operation involving tissue extension, sequential skin eradication, skin grafting, and Z-plasties.³

Lipofilling has been utilized in multiple conditions such as reconstruction/augmentation and correction of hemifacial microsomia asymmetries. The usage of lipofilling in hand expands to diminish hypertrophic

scars after traumatic injuries, in addition to skin regeneration as a cosmetic treatment.⁴

After a split-thickness skin grafting, patients with secondary post-burn scars found a marked increase in flexibility within 3-month follow-up, assessed by the Patient and Observer Scar Assessment Scale (POSA) adhering to a single fat grafting proceeding. Scar shape was changed, and the cases notified a respectable reduction in pain in the scar area.⁵

Nowadays, several studies have shown the beneficial effects of autologous fat grafting on scar contracture and skin quality in different body regions.^{6,7}

Autologous fat grafting has become a process that could be performed as an adjunct procedure to the existing operative therapy, causing potential renewal impacts on the handled position and could decrease tightness and adherence.⁸

As the treatment of severe burn injuries to the hand represents a challenge of great concern, in the present work, we aimed to evaluate the effect of lipofilling in post-burn grafted hands regarding the functional and aesthetic outcome.

PATIENT AND METHODS

Study design: This case serious study was conducted at Al- Azhar University Hospitals in the period from May 2019 to August 2020.

Study Population: Twenty patients with post-burn contracted grafted hands after new hand burn (time of burn was 2 months before fat injection). Patients were complaining of cosmetic and functional complications. All patients included in the study were suffering from a reduced domain of movement because of scar tightness or cosmetically dissatisfying scars but in a good physical case. But, smokers, poor compliance cases, as well as patients unsuitable for operation and even while the patient's joint capsule narrowness/joint toughness is the major reason for a reduced domain of movement, in addition to cases who have extensor deformities (Boutonniere deformity, Swan-Neck deformity, and Mallet finger deformity) are eliminated from the study.

Methods: After counseling all patients and explaining the operation purpose, after operation treatment, and also a potential risk, informed documented consent and photographs were obtained from all patients. Detailed background, specific and generic checks, and complete tests were implemented for the cases. All patients were managed with the same operative technique for autologous fat grafting and 6 months' follow-up.

Preoperative assessment:

Patients' hand functionality evaluation: The before operation evaluation was implemented and involved: 1) Total Active Movement (TAM) evaluated using the stainless steel Goniometer, 2) Every finger was

evaluated as a single identity through overall flexion as well as extending. The TAM of a digit is calculated by supplementing the overall movement of whole the three joints inflection and subtracting the expansion disability from that. In accordance with the American Society for Surgery of the Hand (ASSH) method.⁹

A TAM worth of 2608 is Normal (Metacarpophalangeal (MCP) = 858, Proximal Interphalangeal (PIP) = 1108, Distal Interphalangeal (DIP) = 658):

- 2608 is Excellent,
- 196–2598 is Good,
- 131–1958 is Fair and
- <1308 is Poor.

Evaluation of patient contentment: The patient and observer scar assessment scale (POSAS)¹⁰ was given to whole cases before and after medication. They evaluate vascularity, pigmentation, density, comfort, flexibility, exterior area too, and merge case evaluations of pain, itching, color, toughness, density, as well as comfort.

Surgical procedure: All patients in this study were generally anesthetized.

Fat harvesting and processing: Fat harvesting was done according to the Colman technique¹¹ using a two-hole harvesting cannula with a blunt tip attached to a 50-ml Luer-Lok syringe Figure (1). Afterward, washing of harvested fat by a 20-cc syringe filled with normal saline was performed before fat transplantation according to Fabio Fantozzi's study.¹²

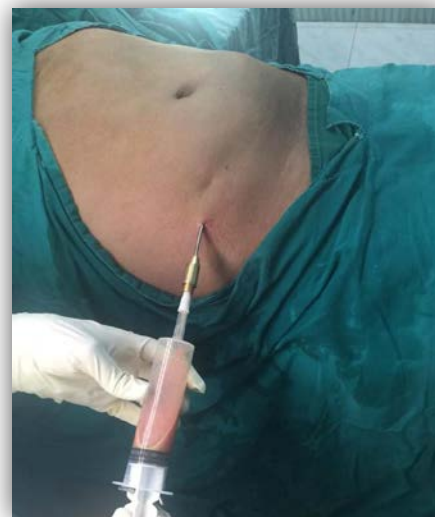

Figure 1: Pulling back on the plunger of a 50-cc syringe to create a slight negative pressure needed to harvest the fat.

Fat injection: was performed one month after healing of graft. A small 1 mm stab incision was performed over the burnt hand dorsum by a No. 11 blade, at a position near to the scar tightness. An infiltration cannula was put in and passed throughout the incision and softly redirected within several moves in a radial pattern, to make tubes for fat injection. Scar

releasing was performed by a V-shaped cannula. The 1 ml syringe tied to the cannula, allowed fat to be put in a radiating fashion, in the area under the skin, in small increases of 0.1–0.2 ml within every pass. The first 8 cases of burn scars treatment were injecting greater amounts that were directly distributed to the fingers or incomplete area by the operator's hand/finger. The last step was injecting more fat into the scar and fullness in density Figure (2). Small excess was carried out in the first 6 cases, however, averted throughout the following cases because we found that placement was very consistent and less possible to extrude from the space narrowness under the skin. All incisions were stitched using 5/0 polyline rapide at the end of the operation.

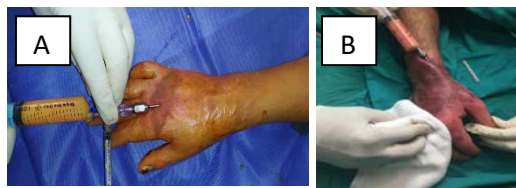

Figure 2: (A,B) Fat injection made by 5 cc syringe connected to infiltration cannula.

Post-operative:

Post-operative care concerning patient's movement, sleep, medications, nutrition, activity, and incisions (Fat transfer entry points, Incisions of fat harvesting) was conducted to all patients.

Follow-up was done at 2 weeks, 1 month, 3 months, and 6 months. Digital photography has been taken for 1 month and 6 months.

Statistics testing: measures were inserted in a Microsoft Excel data table (version 14.4.3, Microsoft Corporation, WA, and USA) and statistical tests were carried out utilizing GraphPad InStat v3 for Macintosh (GraphPad Software, Inc, San Diego, USA). Significance measurements (total active movement, and POSAS scores) were utilized. Statistics indication was made at a p-value of <0.05. Compares were performed for pre and post-fat grafting for the hand itself.

RESULTS

The study included 20 patients divided into 14 females and 6 males with a mean age \pm SD of 32.45 ± 11.74 . 11 patients (55%) were right-handed, while 9 patients (45%) were left-handed. 7 patients (35%) were suffering from a 2nd-degree burn, while 13 patients (65%) were suffering from a 3rd-degree burn. The burn time ranged from 5.0 – 24.0 months with a mean \pm SD of 8.05 ± 4.49 . The burn mode was scald in 7 (35%) patients, and flam in 13 (65%) patients. All patients received a split-thickness (ST) skin graft. The injected fat ranged from (min.=5 ml to max.=15 ml) with a mean \pm SD of 11.55 ± 2.63 . All patients had burns to the dorsum of hand and fingers with physical limitation and tightness and aesthetic disfigure ments. Follow-up for graft healing was

done after three months and 6 months after lipofilling.

Regarding the assessment of hand function, there was a statistical development throughout the total active movement. The before operation TAM developed from a medium of 146 to 1708 postoperatively. Preoperatively most cases (60%) were in the Good/Excellent class, with 40% in the Fair /Poor class; following fat grafting, there was a change in their TAM group with 80% in the Good/Excellent additionally 20% in the Fair/Poor group class after the operation. In this study, there were 8 patients with TAM score preoperative 2600 (excellent) and 8 patients with a score of 2350 (good) they improve to a score of 2600, and 4 patients with a score of 2000 (fair) improve to score (2500).

Regarding the assessment of patient satisfaction (POSAS), pain, itching, scar color, volume, stiffness, and skin-softening were generally improved. There was mild improvement in itching and pain. (P-Value <0.001 for all) Figure (3). Statistical significant developments were found in the total patient POAS score. (P-Value< 0.001) Table (1) Figure (5).

Regarding the assessment of doctor opinion (POSAS), vascularity, pigmentation, pliability, and pain relief were significantly improved (P-Value <0.001) Figure (4). There were statistically significant improvements in the total doctor opinion (POSAS) score (P-Value<0.001) Table (2) Figure (5).

In addition, there were statistically significant improvements in the overall POAS score (P-Value <0.001) Table (3) Figure (5).

Figure 6 and Figure 7 demonstrate two cases of our patient's pre and postoperatively.

In the current study, no complications were encountered after fat grafting in 80% of cases. While in 20% of cases, multiple dehiscences, keloid formation, hypopigmentation, and poor patient compliance were reported Figure (8).

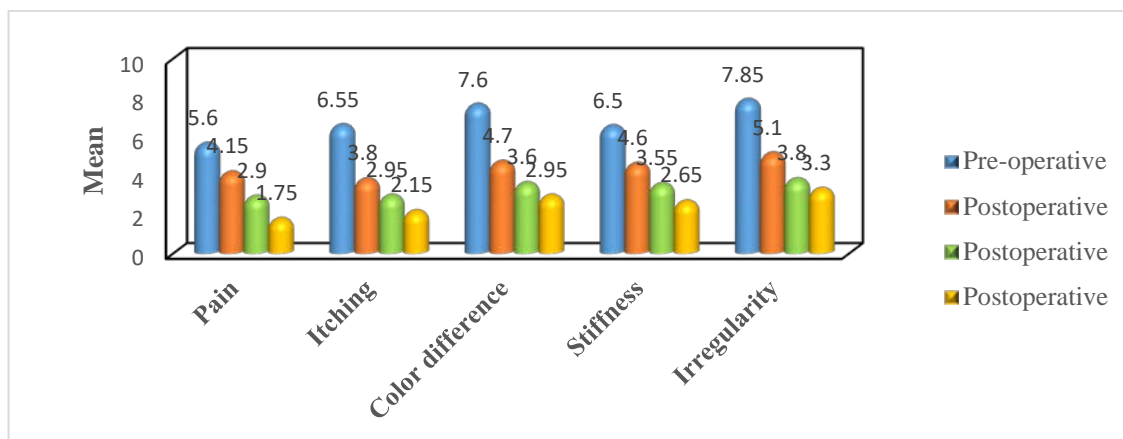


Figure 3: Mean of the patient's opinion at different periods according to pain, itching, color difference, stiffness, thickness, and irregularity.

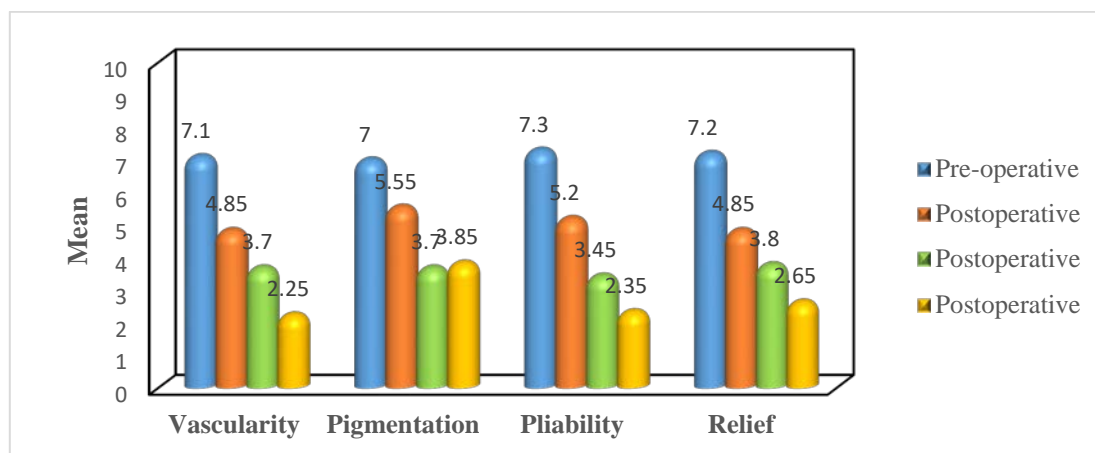


Figure 4: Mean of the doctor's opinion at different periods according to vascularity, pigmentation, pliability, and pain relief.

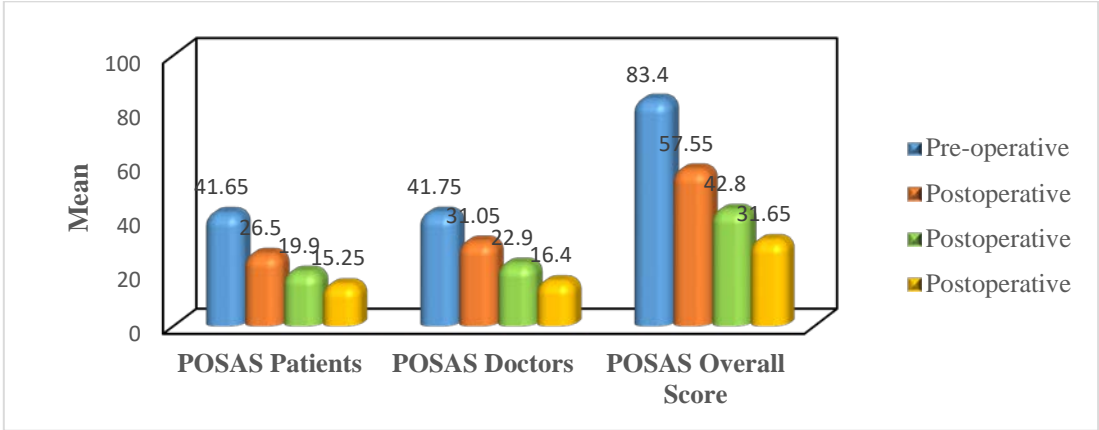


Figure 5: Mean of sore of patients opinion, score of doctors opinion and overall score.

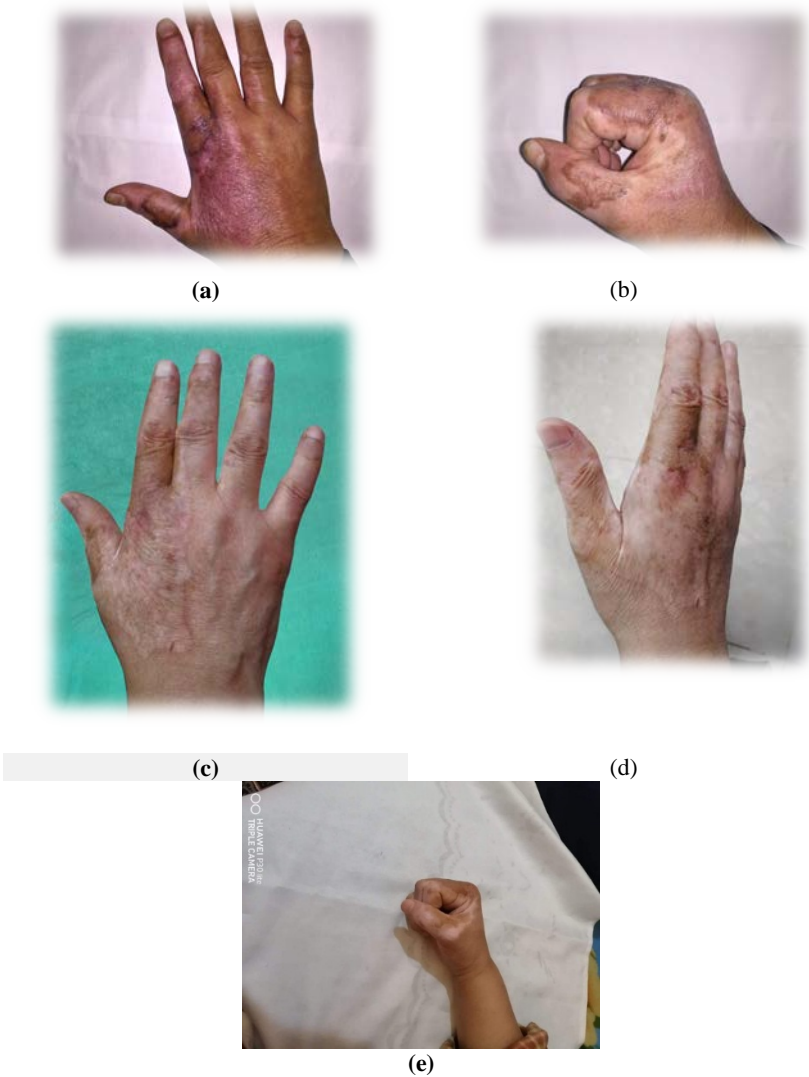
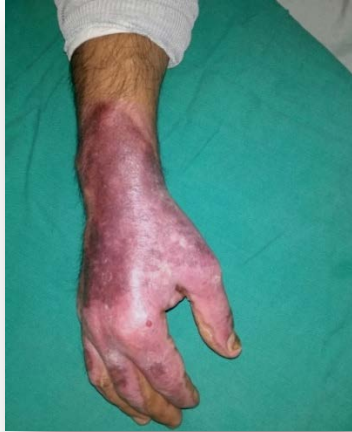
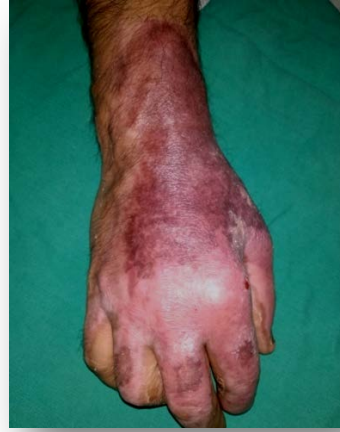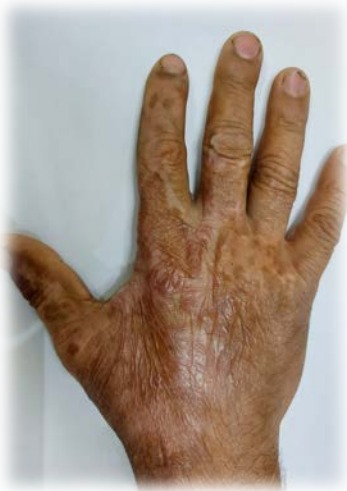Figure 6: 54 years old female presented with post burn scar of right dorsum hand. (a, b) preoperative view of post burn tightness. (c, d) 6 months' post-operative view showing improvement in texture, tightness and skin color on the dorsum of the skin-grafted hand at 6months, (e) 6 months' post-operative view showing improvement in range of motion.



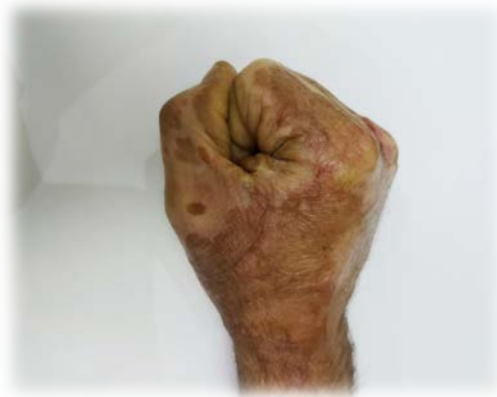(a)



(b)



(c)



(d)

Figure 7: 52 years old male patient presented with post burn contracture of right hand. He is exposed to burn 5 months before presenting to our clinic. (a, b) Pre-operative side view showing scar caused by burn with contracture on dorsum of right hand. (c) 6 months post operative and stiffness.

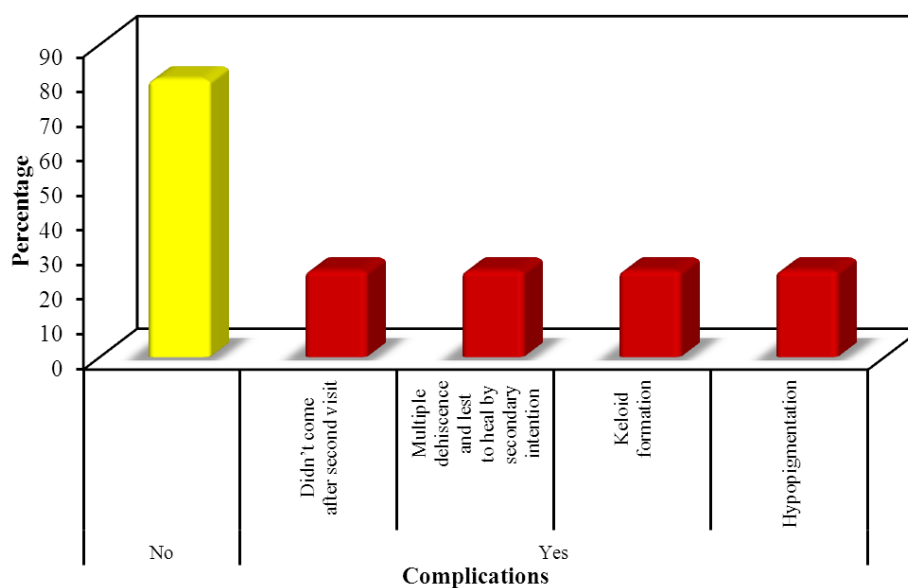


Figure 8: Distribution of the studied cases according to complications

POSAS	Pre-operative	Postoperative			Fr	p
		1month	3month	6month		
Min. – Max.	38.0 – 44.0	19.0 – 32.0	15.0 – 24.0	8.0 – 23.0	57.84 0*	<0.001*
Mean ± SD.	41.65 ± 1.73	26.50 ± 3.65	19.90 ± 2.79	15.25 ± 4.05		
Median (IQR)	42.0(40.5–43.0)	26.5(24.5–29.0)	19.50(18.5–22.0)	15.5(13.0–18.0)		
p ₀		0.014*	<0.001*	<0.001*		
Sig. bet. periods		p ₁ =0.007*, p ₂ <0.001*, p ₃ =0.050				

Table 1: Comparison between the patient's opinion at different periods according to POSAS (n = 20)

Fr: Friedman test, Sig. bet. periods were done using Post Hoc Test (Dunn's)

p: p-value for comparing between the studied periods

p₀: p-value for comparing between pre-operative and each other periodp₁: p-value for comparing between 1month and 3monthp₂: p-value for comparing between 1month and 6monthp₃: p-value for comparing between 3month and 6month

*: Statistically significant at p ≤ 0.05

POSAS	Pre-operative	Postoperative			Fr	p
		1month	3month	6month		
Min. – Max.	30.0 – 48.0	26.0 – 38.0	18.0 – 30.0	11.0 – 32.0	55.800*	<0.001*
Mean ± SD.	41.75 ± 4.40	31.05 ± 3.39	22.90 ± 2.99	16.40 ± 6.56		
Median (IQR)	43.0(41.0–44.50)	30.50(28.5–33.5)	22.0(21.0–25.0)	14.0(13.0–16.0)		
p₀		0.027*	<0.001*	<0.001*		
Sig. bet. periods		p ₁ =0.003*, p ₂ <0.001*, p ₃ =0.086				

Table 2: Comparison between the doctor's opinion at different periods according to POSAS (n = 20)

Fr: Friedman test, Sig. bet. periods were done using Post Hoc Test (Dunn's)

p: p-value for comparing between the studied periods

p₀: p-value for comparing between pre-operative and each other periodp₁: p-value for comparing between 1month and 3monthp₂: p-value for comparing between 1month and 6monthp₃: p-value for comparing between 3month and 6month*: Statistically significant at $p \leq 0.05$

POSAS (overall score)	Pre-operative	Postoperative			Fr	p
		1month	3month	6month		
Min. – Max.	73.0 – 90.0	46.0 – 67.0	33.0 – 48.0	19.0 – 55.0	56.940	<0.001*
Mean ± SD.	83.40 ± 4.38	57.55 ± 4.57	42.80 ± 3.55	31.65 ± 9.29		
Median (IQR)	84.5 (81.5 – 86.0)	58.5 (54.5 – 60.5)	43.0 (41.0 – 45.0)	29.5 (25.5 – 32.5)		
p₀		0.014*	<0.001*	<0.001*		
Sig. bet. periods		p ₁ =0.005*, p ₂ <0.001*, p ₃ =0.086				

Table 3: Comparison between the studied periods according to POSAS overall score (n = 20)

Fr: Friedman test, Sig. bet. periods were done using Post Hoc Test (Dunn's)

p: p-value for comparing between the studied periods

p₀: p-value for comparing between pre-operative and each other periodp₁: p-value for comparing between 1month and 3monthp₂: p-value for comparing between 1month and 6monthp₃: p-value for comparing between 3month and 6month*: Statistically significant at $p \leq 0.05$

DISCUSSION

Fat grafting was utilized in the treatment of scars resulting in a tremendous impact on skin quality.^{13,14}

Unfortunately, hand function is mostly affected by the resulting post-burn scar. Nowadays, fat grafting is increasingly accepted as adjuvant therapy in order to improve the quality of injured skin.¹⁵

The current study was conducted in the department the Plastic Surgery at al-Azhar University Hospital on twenty patients to treat post-burn scar contractures on the dorsum of grafted hands. All patients received one session of autologous fat graft with 6 months follow-up period. The clinical evaluation of the results shows improvement in stiffness, texture, thickness, elasticity, vascularity, and color of the treated skin as well as a reduction of the scar retraction. Fat grafting was done after complete healing of the skin graft.

The donor area is selected in consultation with the patient. In this study, the donor areas were mainly the abdomen and thighs. Fat grafting was done under general anesthesia, only cutaneous and subcutaneous contracture are included after exclusion of any other deformities in hand joints either due to previous trauma or rheumatological diseases.

Huang SH et al, choose the abdomen as a donor site in their study to assess neuropathic scar pain after using autologous fat that is preferable due to the abundance of fat and ease of access with the patient supine.¹⁶

The age of patients in this study was ranging between 6 to 60 years old by mean 32.45 ± 11.74 and the mode of the burn was scald in 7 patients and flam burn in 13 patients with a mean of 11.55 ± 2.63 .

The volume injected was proportional to the extent of scarring and surface area affected. In the present study, the total amount of intraoperative fat injected ranged from 5.0 – 15.0 ml with a mean \pm SD 11.55 ± 2.63 . Klinger et al. suggested that 1 mL AFG for each 3.5 cm² should be used and Piccolo et al. suggested 1.6–2.0 mL per 10 cm².^{14,17}

According to the doctor's opinion in the current study post-operative follow up showed improvement of hand vascularity (color), skin thickness, and skin pigmentation overtime at (2 weeks, 1 and 3 months) interval with a statistically significant difference at p-value $<0.001^*$, $<0.001^*$ and $<0.001^*$. Also, patients reported statistically significant differences regarding them during follow-up.

Riyat et al, study made of a systematic review that assessed the efficacy of AFG in treating scar tissue, in 23 articles. A total of 1158 patients were assessed for improvement in scar characteristics including colour, thickness, volume, pain, and restoration of function at affected sites, following treatment. Positive outcomes were noted for all parameters and

a significant improvement in AFG's analgesic effect was recorded in 567 out of 966 patients, $P < 0.05$.⁽¹⁸⁾

In the current study according to the patient's and doctor's opinion, there was statistically significant better hand pliability at (2 weeks, 1 and 3 months) follow up at p-value $<0.001^*$ and $<0.001^*$ respectively.

A recent study including 40 patients, the majority with adherent postburn scars undergo autologous Fat Grafting found a significant increase in pliability at 3-month follow-up, measured by the Patient and Observer Scar Assessment Scale and the Cutometer following a single fat grafting procedure. Also, scar features were ameliorated, and the patients reported a significant decrease in pain related to the scar.⁵

In the present study according to the doctor's opinion, there was a relief sensation during follow up at (2 weeks, 1 and 3 months) intervals with a statistically significant difference at p-value $<0.001^*$. In addition patients experienced less pain and itching overtime during follow up with statistically significant difference at p-value $<0.001^*$.

In agreement with these results, Fredman et al. focused on the improvement of neuropathic pain in 7 patients with chronic, refractory neuropathic pain, who underwent fat grafting to burn scars and reported improvement of color, texture, contour, pliability, and itching. Six of seven patients had improvement in neuropathic pain after fat grafting.¹⁹

Also, Huang et al. demonstrated a rapid analgesic effect of neuropathic pain, just one week after treatment.⁽¹⁶⁾ This was a significant improvement ($P < 0.05$), using the VAS and NPSI scores. In addition, Lisa et al. suggested that the ADSC create a microenvironment, following tissue regeneration, which encourages nerve release.²⁰

Clinical evaluations of the patient were done according to Patient Observer Scar Assessment Scale (POASA) as it contains four main parameters (vascularity (color), pigmentation, pliability, and height. In our study, overall, POSAS score including (both patients and observer score) mean \pm SD was 84.20 ± 5.37 , 56.45 ± 5.73 and 31.75 ± 9.29 at 2 weeks, 1-month and 3 months respectively with a statistically significant difference at p-value $<0.001^*$.

In the same regards Byrne, M et al. study on thirteen patients who were included in this analysis. The average time from burns and from the fat transfer was 2.3 years (10 months–3.9 years) and 9.1 months (3 months–1.3 years), respectively. There was a statistically significant improvement in TAM measurement. The total score, activity of daily living score, and satisfaction score of the MHQ also statistically increased following fat transfer. For scar assessment, the total score, and the overall score of POSAS improved significantly. Similarly, scores for scar color, scar thickness, scar stiffness, and scar regularity increased significantly.²¹

Also, Klinger et al. reported improvement in all POSAS parameters, both patient and observer after three months of follow-up. All these parameters were significant compared to controls except pain and itching.¹⁴

Despite the advantages of AFG, Riyat et al. reported complications in 14 patients from a total of 1158 patients who were assessed for improvement in scar after fat grafting. This included postoperative hematoma and infection, need for further AFG sessions, and surgical excision of scar tissue following unsuccessful treatment. However, in the current study, no complications were encountered after fat grafting.¹⁸

In this study, we notice that the aesthetic acceptance of our patients was inferior to the surgeon's acceptance and was attributed to the non-realistic expectations of the patients despite well-informed pre-operative consultations. Eight patients (40%) responded as an excellent result while ten patients (50%) responded as good results and two patients (10%) responded as poor results. This is depending on the expectation of the physician and the patient improvement in the patient observer scar assessment scale.

CONCLUSION

Overall, our data suggest autologous fat grafting was superior in post-burn atrophic scars as a good volume filler because of its filling character rather than its good effect on improving the quality of scars through the improvement of scar vascularity, pigmentation, skin thickness, pliability, pain, and itching.

REFERENCES

- Goel A, Shrivastava P. Post-burn scars and scar contractures. *Indian J Plast Surg.*2010;43(Suppl):S63-71.
- Procter F. Rehabilitation of the burn patient. *Indian J Plast Surg.*2010;43(Suppl):S101-13.
- Sunil NP, Ahmed F, Jash PK, Gupta M, Suba S. Study on Surgical Management of Post Burn Hand Deformities. *J Clin Diagn Res.*2015;9(8):Pc06-10.
- Klinger M, Marazzi M, Vigo D, Torre M. Fat injection for cases of severe burn outcomes: a new perspective of scar remodeling and reduction. *Aesthetic Plast Surg.*2008;32(3):465-9.
- Jaspers MEH, Brouwer KM, van Trier AJM, Groot ML, Middelkoop E, van Zuijlen PPM. Effectiveness of Autologous Fat Grafting in Adherent Scars: Results Obtained by a Comprehensive Scar Evaluation Protocol. *Plast Reconstr Surg.*2017;139(1):212-9.
- Al-Hayder S, Gramkow C, Trojahn Køllef SF. Use of autologous fat grafting for the correction of burn scar contracture in the hand: a case report. *Case Reports Plast Surg Hand Surg.* 2017 Aug 24;4(1):81-83. doi: 10.1080/23320885.2017.1369883. PMID: 28971111; PMCID: PMC5613903.
- Ghareeb F, Elsakka D, Alkhateep Y, Zayed H. Improving esthetic outcome of facial scars by fat grafting. *Menoufia Medical Journal.*2017;30(2):412-9.
- Brongio S, Nicoletti GF, La Padula S, Mele CM, D'Andrea F. Use of lipofilling for the treatment of severe burn outcomes. *Plast Reconstr Surg.*2012;130(2):374e-6e.
- Azoury S, John T, Cheema A, Behar B, Zapolsky I, Levin L. American Society for Surgery of the Hand (ASSH) Presidential Address Themes, 1964-2018: Revisiting Our History as We Move Forward. *Journal of Hand Surgery Global Online.*2020;2.
- Chae JK, Kim JH, Kim EJ, Park K. Values of a Patient and Observer Scar Assessment Scale to Evaluate the Facial Skin Graft Scar. *Annals of dermatology.*2016;28(5):615-23.
- Coleman SR. Hand rejuvenation with structural fat grafting. *Plast Reconstr Surg.*2002;110(7):1731-44; discussion 45-7.
- Fantozzi F. Hand rejuvenation with fat grafting: A 12-year single-surgeon experience. *European Journal of Plastic Surgery.*2017;40.
- Gimble JM, Guilak F. Differentiation potential of adipose derived adult stem (ADAS) cells. *Curr Top Dev Biol.*2003;58:137-60.
- Klinger M, Caviggioli F, Klinger FM, Giannasi S, Bandi V, Banzatti B, et al. Autologous fat graft in scar treatment. *J Craniofac Surg.*2013;24(5):1610-5.
- Rigotti G, Marchi A, Galiè M, Baroni G, Benati D, Krampera M, et al. Clinical treatment of radiotherapy tissue damage by lipoaspirate transplant: a healing process mediated by adipose-derived adult stem cells. *Plast Reconstr Surg.*2007;119(5):1409-22.
- Huang SH, Wu SH, Chang KP, Lin CH, Chang CH, Wu YC, et al. Alleviation of neuropathic scar pain using autologous fat grafting. *Ann Plast Surg.*2015;74 Suppl 2:S99-104.
- Piccolo NS, Piccolo MS, de Paula Piccolo N, de Paula Piccolo P, de Paula Piccolo N, Daher RP, et al. Fat Grafting for Treatment of Facial Burns and Burn Scars. *Clin Plast Surg.*2020;47(1):119-30.
- Riyat H, Touil LL, Briggs M, Shokrollahi K. Autologous fat grafting for scars, healing and pain: a review. *Scars Burn Heal.*2017;3:2059513117728200.
- Fredman R, Edkins RE, Hultman CS. Fat Grafting for Neuropathic Pain After Severe Burns. *Ann Plast Surg.*2016;76 Suppl 4:S298-303.
- Lisa A, Murolo M, Vinci V, Maione L, Klinger F, Klinger M. Alleviation of Neuropathic Scar Pain Using Autologous Fat Grafting. *Ann Plast Surg.*2016;76(4):474.
- Byrne M, O'Donnell M, Fitzgerald L, Shelley OP. Early experience with fat grafting as an adjunct for secondary burn reconstruction in the hand: Technique, hand function assessment and aesthetic outcomes. *Burns.*2016;42(2):356-65.