

Conservative Treatment of Grade III Acromioclavicular Joint Dislocation

Eissa Ragheb Refaie¹MD, Emad Mohamed Zayed¹MD, Islam Abdel-Baset Hashim^{1,*} MB BCh

Orthopedic Surgery

*Corresponding Author:

Islam Abdel-baset Hashim
islam20hashim@gmail.com

Received for publication
December 13, 2019; Accepted
January 10, 2020; Published
on line January 27, 2020

Copyright 2020 The Authors
published by Al-Azhar
University, Faculty of Medicine,
Cairo, Egypt. All rights reserved.
This an open-access article
distributed under the legal terms,
where it is permissible to
download and share the work
provided it is properly cited. The
work cannot be changed in
anyway or used commercially.

doi: 10.21608/aimj.2020.20914.1017

¹ Orthopaedic Surgery
Department, Faculty of
Medicine - Al-Azhar University

Abstract

Background: The acromio-clavicular (AC) joint stability depends on the acromio-clavicular ligaments, the coraco-clavicular (CC) ligaments, and the joint capsule. Treatment of acute type III injuries still controversial. We evaluated the results of conservative treatment of type III AC joint dislocation according to clinical and radiological outcome.

Patients and Methods: This prospective study included fifteen patients with acute acromio-clavicular joint dislocations type III. There were one woman and fourteen men, with an average age of 29.7 ± 10.2 years. All patients underwent clinical assessment according to Constant score and a radiographic study (antero-posterior showing both shoulders, axillary views). All patients were treated conservatively and followed up for 6 months.

Results: Eleven patients out of fifteen were satisfied. The mean constant score improved from 39.6 ± 8.2 at the time of trauma to 87.3 ± 10 after 6 months follow up with statistically significant difference ($p < 0.001$). The mean of Corac-Clavicular distance difference improved from 58 ± 18.8 at time of trauma to 39.7 ± 8 after 6 months.

Conclusion: Conservative treatment of acromio-clavicular joint dislocation type III gives acceptable results with a low rate of complications especially in early diagnosed and treated patients, with sedentary life, and with less widening of Corac-Clavicular distance.

Keywords: Coraco-Clavicular (CC) ligament, acromio-clavicular (AC) dislocation, conservative treatment

Disclosure: The authors have no financial interest to declare in relation to the content of this article. The Article Processing Charge was paid for by the authors.

Authorship: All authors have contributed to the article.

INTRODUCTION

Dislocation of Acromioclavicular (AC) joint is a common injury representing about 9% of all shoulder injuries¹. Rockwood² classified AC joint dislocation into six types. He reported that classification Tossy et al³ did not provide adequate categorization of all patterns of injury. The ISAKOS (International Society of Arthroscopy, Knee Surgery & Orthopaedic Sports Medicine) modify Rockwood classification by further subdividing the type III AC joint injuries into type IIIA (stable) and type IIIB (unstable).⁴

Radiographic examination includes anteroposterior, axillary views, and zanca views. A cross-body adduction radiograph (so-called Basamania view) was reported to differentiate between a stable and unstable AC joint.⁴ Across body adduction AP view of the AC joint is used to assess the degree to which the clavicle overlaps the acromion because of the anteromedial translation of the scapula. If the clavicle overrides the acromion in this view, it indicates instability of the CC ligaments in addition to the AC joint disruption.⁴

Type I and II dislocations treated conservatively.^{2,4,5,6} The acute types IV-VI dislocation generally require surgical repair.^{4,7,8,9} Management of acute type III injuries has been controversial, despite randomized trials that indicate success with nonoperative treatment in most cases.^{2,4,5,7,9} A recent operative treatment includes repair of CC ligaments augmented with metallic buttons or either by arthroscopic or open surgery.^{9,10}

PATIENTS AND METHODS

This prospective study was approved by ethical committee of Al-Azhar university included 15 patients with Rockwood type III acute AC joint dislocations. They treated conservatively at the department of orthopedic and traumatology Al-Azhar university hospitals during the period from July 2018 to June 2019.

We included fifteen patients with recent grade III acromio-clavicular joint dislocation, other grades excluded; also, patients with chronic AC dislocation and dislocation associated with fractures around shoulder excluded.

The study included fourteen men and a woman, with a mean age of 29.7 ± 10.2 years (17–54 years). In nine cases the dislocation had been caused by an accidental fall during working activities, three cases sustained in road traffic accident, and three cases while practicing sport activities. Ten patients were manual workers with overhead activities and 5 patients had sedentary life.

All the patients underwent complete general and local clinical examination (Fig. 1). We followed the patients for pain, activity level, arm positioning, strength of abduction in pounds, and range of motion according to Constant score.¹¹ Radiographic examinations (Antero-posterior view showing both shoulders (Fig. 2), and Axillary view)(Fig. 3) were done to assess type of dislocation. Coraco-clavicular distance was measured bilaterally in AP view from most superior point of the base of coracoid process to the inferior surface of the clavicle (Fig. 2). Coraco-clavicular distance difference (CCDD) (which represents the absolute difference in displacement between injured and non-injured sides) was measured at time of trauma and after 6 months follow up.

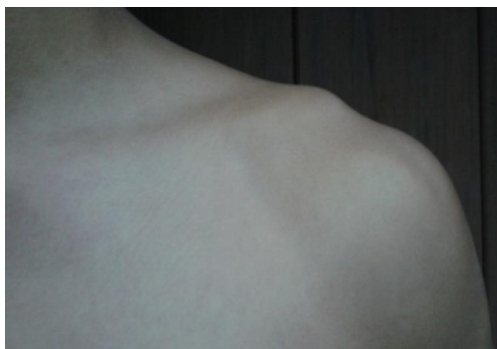

Fig. 1: Acromio-Clavicular (AC) joint dislocation- left shoulder

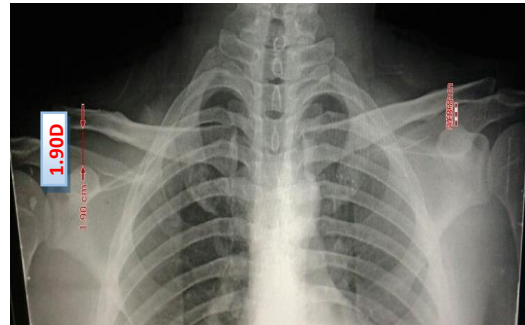


Fig.2: Antero-posterior view showing both shoulders with red arrows at coraco-clavicular distance.

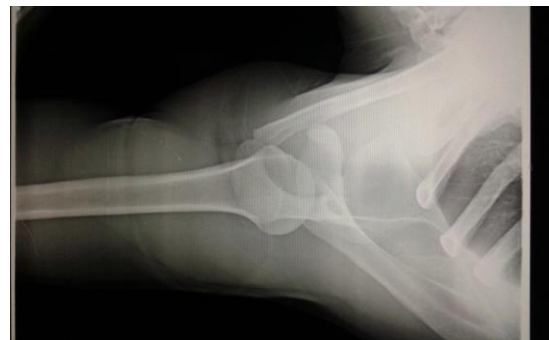

Fig. 3: Axillary View

Non operative treatment consisted of sling support , ice applied for the first 48 hours, symptomatic treatment with nonsteroidal anti-inflammatory medication, and early mobilization of fingers, elbow and wrist . Patients instructed to avoid overhead use of the arm .After the 2 weeks the arm sling discontinued as symptoms subside and strengthening exercises are instituted. Consideration of range of motion, strength, and pain assisted in determining when the patient may return to unrestricted activity. Rehabilitation involved range of motion and isometric exercises progressing to isotonic exercises. Closed chain exercises performed in order to separate scapular movement into individual motions. Our result was evaluated by Wilcoxon signed ranks test and Paired t-test, P value ≤ 0.05 was considered statistically significant

RESULTS

All the patients were followed for 6 months. Functional outcomes were recorded at the time of trauma and after 6 months from the onset of injury. The mean Constant score improved from 39.6 ± 8.2 at the time of trauma to 87.3 ± 10 after 6 months follow

up with statistically significant difference ($p < 0.001$) (Table 1).

Clinically, 10 patients had no pain, 2 patients had mild pain and 3 patients had moderate pain. Full forward flexion in 12 patient and 3 patients had forward flexion up to 150° . 10 patients had full work and 5 patients had moderate limitation of daily activities. The cross-body adduction test was negative in 13 patients. The mean of CC distance difference improved from $58 \pm 18.8\%$ at time of trauma to $39.7 \pm 8\%$ after 6 months of conservative treatment with statistically significant difference ($p < 0.006$) (Table 2). Eleven out of fifteen patients were satisfied. The main complains of the unsatisfied patients were residual pain, especially at carrying heavy objectives and above head activities and residual deformity. The four patients underwent intraarticular injection with corticosteroids, 2 patients were satisfied with injection and 2 patients were not. One patient

underwent operative treatment in the form of open reconstruction of coracoclavicular ligament using autograft and Tight Rope.

We found that the result of conservative treatment in patient involved in sports and works with overhead activities is less good than those had sedentary life with statistically significance ($p0.030$). There was no statistically correlation between the age and Constant Score ($p0.269$), however the age inversely proportional to the Constant Score. There is a statistical correlation between the time passed till 1st presentation and the constant score after 6 months ($p < 0.001$) patients early treated give best result. There is statistical correlation between CC distance at time of trauma and Constant Score after 6 months ($p 0.002$). The more the CC distance the less the Constant score.

No	Age	Sex	Sorts/above head	Time of 1 st presentation (day)	Constant score at time of trauma	Constant Score at 6 m. follow up
1	28	M	No	1	36	87
2	38	M	Yes	1	34	93
3	17	M	No	2	51	93
4	21	M	Yes	5	30	81
5	34	M	Yes	4	42	93
6	19	F	Yes	1	43	94
7	26	M	Yes	7	32	72
8	18	M	Yes	1	42	91
9	24	M	No	3	48	90
10	54	M	Yes	11	30	66
11	32	M	No	1	42	98
12	29	M	Yes	1	45	98
13	39	M	No	1	56	98
14	41	M	Yes	5	30	81
15	26	M	Yes	10	33	74
MEAN \pm SD	29.733 \pm 10.173			3.783 \pm 4.667	39.6 \pm 8.2	87.3 \pm 10
Paired t-test						-27.756
P-value						<0.001 (HS)

Table (1): Data and clinical outcome of fifteen patients with conservative treatment of acute AC joint dislocation grade III.

No	CC distance difference (%) at time of trauma	CC distance difference (%) at 6 m. follow up
1	40%	35%
2	42%	35%
3	50%	38%
4	65%	45%
5	38%	30%
6	37%	36%
7	90%	40%
8	83%	32%
9	55%	37%
10	70%	55%
11	45%	35%
12	52%	38%
13	40%	35%
14	78%	48%
15	85%	57%
MEAN±SD	58 ± 18.8%	39.7 ± 8%
Paired t-test	4.585	
P-value	<0.001 (HS)	

Table (2) :Coraco-clavicular distance difference (%) at time of trauma trauma and after 6 m. follow up

DISCUSSION

Despite the large volume of studies on acromioclavicular injuries there is significant controversy over the proper treatment of type 3 AC injuries. Although non-operative treatment does not restore anatomic alignment of the AC joint, this treatment facilitates early rehabilitation. While operative treatment, on the other hand, attempts to restore the anatomy, this treatment can be associated with a variety of complications.⁹

In our study, the mean Constant score improved from 39.6 ± 8.2 at the time of trauma to 87.3 ± 10 after 6 months follow up with statistically significant difference ($p < 0.001$). The mean of CC distance difference improved from $58 \pm 18.8\%$ at time of trauma to $39.7 \pm 8\%$ after 6 months of conservative treatment with statistically significant difference ($p < 0.006$). 75 % of our patients were satisfied with the result of conservative treatment.

A Cochrane⁹ review done for comparison between non-operative and operative treatment for type 3 injuries. The inclusion criteria were all randomized or nonrandomized trials that compared non operative and operative treatment in adult patients. This review included Three studies . The three studies included 174 patients treated with different procedures. They found insufficient evidence from randomized controlled trials to determine if surgical treatment is

indicated for type 3 AC joint dislocations in adults in the current literature. All of the trials included done many years ago and none of them included the recent advancements in anatomic reconstructive techniques. Also, all of the clinical outcome measurements were done with non-validated point system scores. Based on this limited data, it is difficult to make definitive recommendations on non-operative versus operative management of these injuries.⁹

As maximilian et al¹² reported, we found there is a statistical correlation between the time passed till 1st presentation and the constant score after 6 months ($p < 0.001$), patients early treated give best result. Although Vasellari et al.¹³ reported that there is no correlation between Coraco-clavicular distance difference and outcome ,in our study we found a statistical correlation between CC distance difference at time of trauma and Constant score after 6 months ($p 0.002$).The more the CC distance the less the Constant Score.

ISAKOS reported that initial nonsurgical treatment is preferred in type III dislocations in most cases. They classified type 3 injury into type IIIA and type IIIB lesions for differentiation and identification of patients who would benefit from surgical intervention. They recommend that all patients presenting with type III instability initially undergo treatment with 3 to 4weeks of nonsurgical

management. Some of these conservatively treated patients will have persistent pain and an inability to return to their sport or activity. Subsequent surgical stabilization, although delayed, will still allow eventual return to sport or work in such cases.⁴

Limitation: The limitation of our study is that the small sample we involved in the study and short duration of follow up.

CONCLUSION

Despite the large volume of studies on acromioclavicular injuries there is significant controversy over the proper treatment of type 3 AC injuries. Conservative treatment of AC joint disruption grade III give acceptable result especially in early diagnosed and treated, with sedentary life, and with less widening of CC distance.

REFERENCES

1. Chillemi C, Franceschini V, Dei Giudici L, et al. Epidemiology of isolated acromioclavicular joint dislocation. *Emerg Med Int.* 2013; 2013:171609. doi: 10.1155/2013/171609. Epub 2013 Jan 28.
2. Cho CH, Hwang I, Seo JS, et al. Reliability of the classification and treatment of dislocations of the acromioclavicular joint. *J Shoulder Elbow Surg.* 2014; 23(5):665-70. doi: 10.1016/j.jse.2014.02.005.
3. Mazzocca D, Santangelo A, Johnson T, et al. A biomechanical evaluation of an anatomical coracoclavicular ligament reconstruction. *Am. J Sports Med* 2006; 34:236-246.
4. Rockwood C. Fractures and dislocations of the shoulder. In: Rockwood CA Jr, Green DP, editors. *Fractures in Adults.* Philadelphia, Lippincott, 1984.
5. Buss D and Watts D. Acromioclavicular injuries in the throwing athlete. *Clin Sports Med.* 2003;22(2):327-41
6. Garretson III B and Williams G Jr. Clinical evaluation of injuries to the acromioclavicular and sternoclavicular joints. *Clin Sports Med.* 2003;22(2):239-54
7. Tossy J, Mead N and Sigmond M. Acromioclavicular separations: useful and practical classification for treatment *Clin Orthop Relat Res.* 1963; 28:111-9.
8. Lizaar A, Marco L and Cebrian R. Acute dislocation of the acromioclavicular joint . Traumatic anatomy and the importance of deltoid and trapezius *J Bone Joint Surg Br.* 1994;76(4):602-6.
9. Rockwood C, Williams G Jr and Young C. Disorders of the acromioclavicular joint. In: Rockwood CA Jr, Masten FA III, editors. *The shoulder.* Ed 2. Philadelphia: WB Saunders, 2000; 483-553.
10. Fukuda K, Craig V, An N, et al. Biomechanical study of the ligamentous system of the acromioclavicular joint. *J Bone Joint Surg* 1986; 68(A):434-40.
11. Phillips A, Smart C and Groom AF. Acromioclavicular dislocation. Conservative or surgical therapy. *Clin Orthop Relat Res.* 1998; 353:10 -7.
12. Bannister G, Wallace W, Stableforth PG, et al. The management of acute acromioclavicular dislocation. A randomised prospective controlled trial. *J Bone Joint Surg Br.* 1989; 71(5):848-50.
13. Taft T, Wilson F and Oglesby J. Dislocation of the acromioclavicular joint. An end-result study. *J Bone Joint Surg* 1987; 69(A):1045-51.
14. Larsen E, Bjerg A and Christensen P. Conservative or surgical treatment of acromioclavicular dislocation. A prospective, controlled, randomized study. *J Bone Joint Surg Am.* 1986; 68(4):552-5.