

Evaluation of surgical versus VASER assisted liposuction in management of submental adiposity in moderate to severe skin laxity and significant lipodystrophy

Ahmed Gamal Borhamy¹ MSc; Ahmed Taha Sayed² MD; Abd El Monem Hota² MD.

* Corresponding Author:

Ahmed Gamal Borhamy
prainpower@yahoo.com

Received for publication September 2, 2021; Accepted November 8, 2021; Published online November 8, 2021.

Copyright The Authors published by Al-Azhar University, Faculty of Medicine, Cairo, Egypt. Users have the right to read, download, copy, distribute, print, search, or link to the full texts of articles under the following conditions: Creative Commons Attribution-Share Alike 4.0 International Public License (CC BY-SA 4.0).

doi: 10.21608/aimj.2021.93958.1562

¹Plastic and Reconstructive Surgery and burn Department, Ministry of health hospitals, Cairo, Egypt.

²Plastic and Reconstructive Surgery and burn Department, Faculty of Medicine, Al-Azhar University, Cairo, Egypt.

INTRODUCTION

Excess submental fat, also referred to as a "double chin," is a popular cosmetic concern among today's patients. Fortunately, less intrusive techniques are now available for treating this previously hard to reach anatomic region.¹

A double chin can ruin the profile, making the person appear overweight or aged. A smooth, sculpted neck and chin are symbols of classic beauty and youthful looks for females. A chiseled jawline in males symbolizes strength and perseverance. Excess fat in these areas blur these effects, known medically as submental fat, a double chin can be difficult to resolve.²

Facial and neck aging is a multifaceted process that affects all layers of the skin, subcutaneous tissues, and bones. Excessive skin laxity is a clinical manifestation of the progressive erosion of dermal structural integrity over time.³

ABSTRACT

Background: Submental adiposity is one of visible signs of the aging process which affects the aesthetic look of the face and neck, and its management usually is difficult without surgery, nowadays we can achieve a good result in double chin without surgical lifting of neck by new technology (VASER liposuction) in many cases.

Aim of the study: To evaluate the surgical versus VASER assisted liposuction in management of submental adiposity in moderate to severe skin laxity and significant lipodystrophy.

Patients and Methods: This study is prospective study was conducted on 30 male and female patients starting from September 2018 till March 2021, in Al-Azhar university hospitals presented with moderate or severe submental adiposity (double chin), were categorized in random fashion into two groups, Group (A) management by ultrasound assisted liposuction VASER (15 patient), Group (B) surgical management (neck lifting) (15 patient).

Results: Regarding patient acceptance, among the VASER group, 6 patients (40%) reported good score, 5 patients (33.3%) reported very good score, 4 patients (26.7%) reported fair score. While 10 patients (66.7%) reported very good score, 3 patients (20%) reported excellent score and 2 patients (13.3%) reported good score.

Conclusion: Surgical neck lifting showed best result, especially in old age when compared with VASER liposuction that have a good results in young and middle ages.

Keywords: VASER; Neck liposuction; Submental fat.

Disclosure: The authors have no financial interest to declare in relation to the content of this article. The Article Processing Charge was paid for by the authors.

Authorship: All authors have a substantial contribution to the article.

Submental fullness is typically treated with liposuction. Nevertheless, the success of this method is contingent on the patient's skin's quality. Over suctioning of the fat and damage to the marginal mandibular nerve may cause contour abnormalities. Furthermore, isolated submental liposuction might not entirely treat submental fullness and the ageing face; thus, a cervicoplasty combining open liposuction and platysmaplasty has been preferred.⁴

Changes in deeper structures accompany the changes in skin which happen with aging. As people get older, their basal metabolic rate decreases, which leads to an increase in adipose tissue formation. Starting in the 5th decade, proportionate rises in fats are visible in the face. Under the superficial fascia, fatty tissue builds up in depot locations of the body. These areas are situated in the periorbital, malar, and submental areas of the neck and face.⁵

Plastic surgeons are now performing liposuction as one of their most common operations. Traditional liposuction has had a variety of advancements throughout the years, resulting in increased surgeon comfort and improved outcomes.⁶

Any modified liposuction procedure which provides ultrasonic energy to subcutaneous fat in terms of facilitating conventional negative pressure liposuction is known as ultrasound-assisted liposuction (UAL).⁶

“Amplification of Sound Energy by Vibration at Resonance.” is what the VASER stands for. The VASER Liposelection system has been a 4th generation of ultrasonic technique that targets only adipocytes and utilizes an innovative, patented fat elimination method that does not damage surrounding components such as nerves, blood vessels, and collagen bundles.⁷

VASER assisted liposuction of the submental area is typically performed to remove the superficial fatty deposit (supraplatysmal fat) with the premise that the overlying skin will contract and “tighten up.” Obviously through collagen neogenesis to obtain optimal results. It is a well-known fact that the age of the patient has a direct correlation with the tone and laxity of the skin; younger patients have more elasticity and tone to their skin compared with older patients. This fact explains why submental skin can contract and tighten after liposuction in the younger patient population.⁸

When compared to cervicoplasty, submental liposuction is a less difficult operation. It could be conducted using either the closed or open technique with minimum instrumentation. Liposuction of the submental region is commonly used to eliminate a superficial fatty deposit (supraplatysmal fat) in the hopes that the overlying skin would shrink and “tighten up.” Incorrect approach, especially injury to the subdermal plexus, may clearly result in adverse outcomes.⁴

This research aims to Evaluation of surgical versus VASER assisted liposuction in management of submental adiposity in moderate to severe skin laxity and significant lipodystrophy and to evaluate other optional technique being for skin tightening without big surgical incision and patient satisfaction of excellent results with scars or good results without scars.

PATIENTS AND METHODS

This study is prospective study was conducted on 30 male and female patients starting from September 2018 till march 2021, in Al-Azhar university hospitals presented with moderate or severe submental adiposity (double chin), were categorized in random fashion into two groups: Group (A): management by ultrasound assisted liposuction

VASER (15 patient). Group (B): surgical management (neck lifting) (15 patient).

Inclusion criteria:

Male or female patients.
Age from 21 to 70 years.
Suffering from submental adiposity moderate and sever degree.

Exclusion criteria:

Chronic diseases as diabetes mellitus.
Infectious diseases as hepatitis.
Bleeding disorders.
Body mass index (BMI) > 40.
Congenital disease of mandible as micrognathia.

Methods:

Our study had selected two groups of patients; both could be suitable candidate for submental rejuvenation by VASER liposuction or surgery. Cases complaining of redundant submental fat and moderate to severe skin laxity of the neck and jowls were included in the study as type III and type IV patients, as per the Rod J. Rohrich et al.⁹ classification, where type III patients have Moderate Skin Laxity with or without Wide Platysmal Bands (>2 cm) and type IV patients have Moderate-Severe Skin Laxity with considerable Lipodystrophy.

Palpation of: submental fat by pinch test detection of skin elastosis, position of submandibular gland, lymph nodes in neck, thyroid gland.

VASER Liposuction group

Marking the patient neck in standing position, to delineate the area to be treated. Patients should be informed of the possibility of a second operation, so that they do not interpret persistent some laxity of skin as a surgical failure. Preoperative antibiotic of 1g of ceftriaxone was given. The operation was done by local anesthesia with sedation, and if the double chin liposuction is a part from another operation like breast reduction or etc. the anesthesia was general.

First, local injection of xylocaine 2% diluted 50% by saline in different sites in submental and neck areas with sedation as local anesthesia in awake patient. Then, Tumescence local anesthetic solution prepared as 1ml of adrenaline (epinephrine) and 20 ml of xylocaine 2% add to 500 ml of Normal saline (0.9% sodium chloride). Small incision 2 mm by scalpel no. 11 in sub mental crease and post auricular in both sides. A 2-mm, sharp, sprinkler-tipped or multiple opening infiltration cannula, 15 cm or 25 cm long, is used for infiltration of tumescent solution. Neck infiltration can be done using 20–50-cc injections or an infiltrating pump then waiting about 15 minutes.

Start by VASER device zeron company, ultra z model, from Korea, the preparation of device is 70%

for skin tightening and 30% for lipolysis in young patients, and 90% tightening for old patients (recommendation of the company).

Skin tightening and lipolysis done be interduce the short canula 15 cm of the device for 2 minutes duration, then, start to do traditional liposuction with low pressure by suction machine or by syringes, using small canula no. 3, and the opening of the canula directed away from the facial nerve's marginal mandibular branch. Determined the skin thickness immediate post-operative. The opening closed by simple one suture by proline 6-0. Without drain insertion. Compression on the neck by one or two neck wrap according to the surface of liposucted areas for 2 weeks.

Surgical group

Surgical technique of submental incision:

The same steps in VASER group, marking, anesthesia, tumescent infiltration, traditional liposuction. The incision is roughly 3-4 cm in length and is performed in the submental region, posterior to the existing crease. The incision is made in the subcutaneous tissue, which leads to the underlying fat. Under direct visualization, the neck skin is elevated to form a sufficiently thick skin flap bilaterally to the sternocleidomastoid, anteriorly towards the chin, and inferiorly towards the base of the neck. To contour the neck, the fat overlying the platysma has been excised with scissors whereas the underlying muscle is carefully protected. Next that, muscle excess was assessed and removed with a vest-over-pants platysmorrhaphy performed with 4-0 vicryl suture. After closing the submental incision using 6-0 Monocryl, Steri-strips are placed. For at least 10 days, a cervical pressure garment is worn.

Surgical technique of vertical scar (face and neck left):

The same steps in VASER group, marking, anesthesia, tumescent infiltration, traditional liposuction. Access is gained by pre- and post-auricular incisions. In the midline submental region, which connects the two skin flaps, there is extensive undermining of both the cheeks and the submandibular area. Using a head light, all dissections are carried out under direct vision. A minimum of 3 mm of subcutaneous fat has been left on the skin flap to avoid obvious skin abnormalities, adhesions, and dimpling. In order to define the final postsurgical look of the neck, meticulous sculpting of the extra fat from the platysma is required. Release of the mandibular cutaneous ligaments. The sternocleidomastoid fascia's lateral platysmal plication or mastoid facia for a more horizontal pull, is performed with multiple 4-0 PDS suture. Following the excision of excess skin, the residual skin is redraped with no tension. Elevation of the patient's blood pressure before closure to a supranormal level for hemostasis. Insertion of

suction drain bilateral (in some cases) and exit from post auricular wounds (not in all cases) then closure of the wound in layers by subcutaneous vicryl 5-0 and skin by 6-0 proline. The drain is withdrawn on postsurgical day 3 or 4, and a cervical pressure garment can be worn for a minimum of three weeks. Suture was removed after 10 days. Follow up the patient at 4, 10, 21 days post-operative and follow up of the scar after 6 months. We assessed the scar according to the scar score.

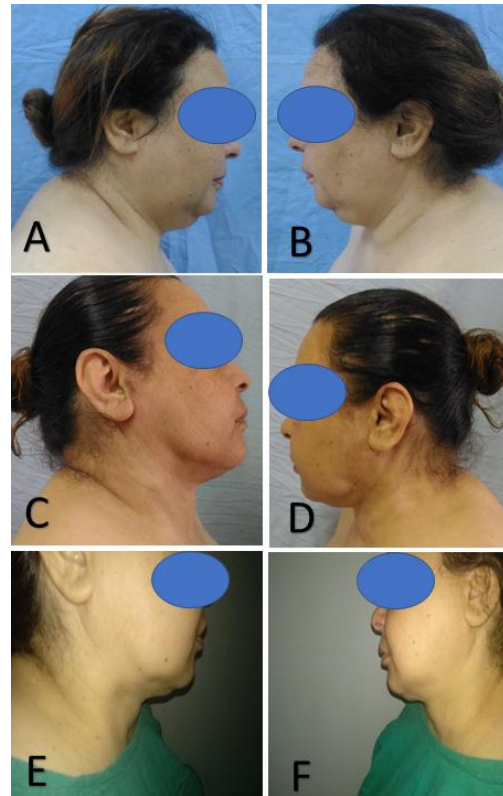

Fig 1: Female patient, suffered from Moderate-Severe Skin Laxity and Significant Lipodystrophy, grade IV, (A & B)before surgery , (C&D) after 3 months of VASER assisted liposuction , (E&F) after 1 year which become grade II, note that mild skin laxity.

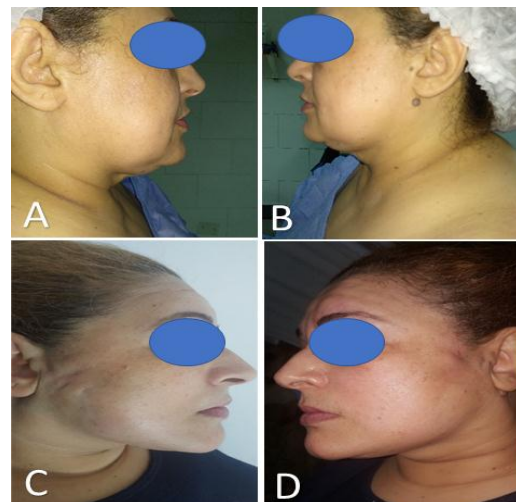

Fig 2: Female patient, suffered from Moderate Skin Laxity and Significant Lipodystrophy, grade III, (A & B)before surgery , (C&D) after 6 months of VASER assisted liposuction ,(which become grade I).

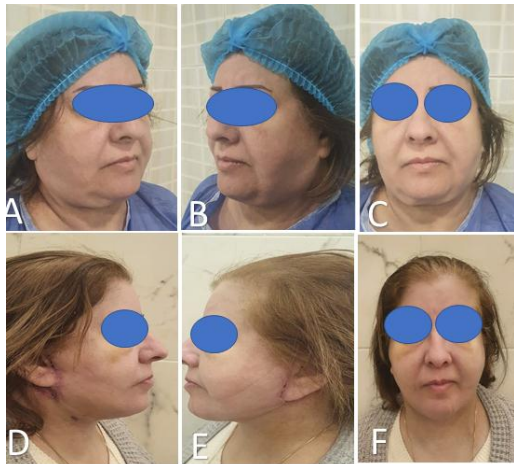


Fig 3: Female patient, suffered from Moderate Skin Laxity and Lipodystrophy, grade III, (A, B & C)before surgery , (D, E & F) after 2 weeks of vertical scar (face and neck lift), which become grade I.

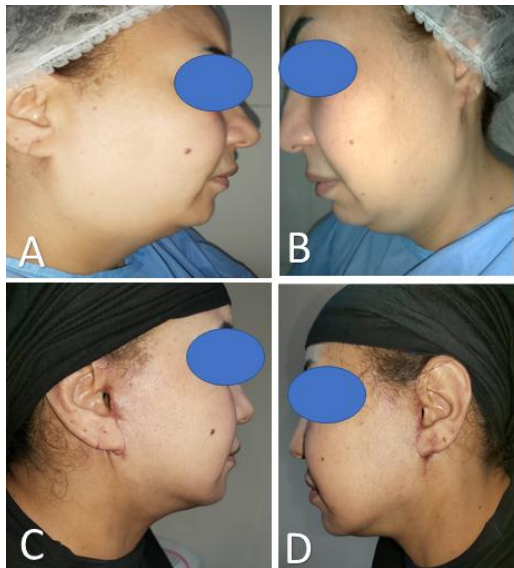


Fig 4: suffered from Moderate Skin Laxity and Lipodystrophy, and obtuse cervicomenal angel , grade III, (A & B)before surgery , (C&D) after 5 months of vertical scar (face and neck lift), which become grade I.

RESULTS

The current study was carried out on 30 patients; 15 patients underwent the VASER technique while 15 patients underwent the surgical lift technique.

Comparison between the studied groups according to pre- operative skin pinch test:

Preoperative skin pinch tests in the VASER group ranged between (1.3-2.5) cm with a mean ± SD of 1.85±0.39. While preoperative skin pinch tests in the surgical group ranged between (1.2 – 2.1) cm with a mean ± SD of 1.7 ± 0.29. There was no statistically significant difference between the studied groups according to the preoperative test (p=0.251) (Table 1).

Postoperative skin pinch tests in the VASER group ranged between (0.3 – 0.6) cm with a mean ± SD of 0.467 ± 0.105 cm. While postoperative skin pinch tests in the surgical group ranged between (0.4- 0.6) cm with a mean ± SD of 0.50 ± 0.076 cm. There was no statistically significant difference between the studied groups according to the postoperative skin pinch test (p=0.383) (Table 2).

The operative time in the VASER group ranged between (50 – 110) minutes with a median of 70 minutes. The operative time in the surgical group ranged between (150 – 300) minutes with a median of 240 minutes. There was a high statistically significant difference between the two studied groups as regards the operative time (p<0.0001) (Table 3).

Comparison between the two studied groups according to the degree of double chin:

Regarding pre-operative grading, among the VASER group, one patient (6.7%) was grade II, 10 patients (66.7%) were grade III, 4 patients (26.7%) were grade IV. While among the surgical group, 3 patients (20%) were grade II, 10 patients (66.7%) were grade III, and 2 patients (13.3%) were grade IV. There was no statistically significant difference between the two studied groups as regards pre-operative grading (p=0.489). (Table 4; Figure 5).

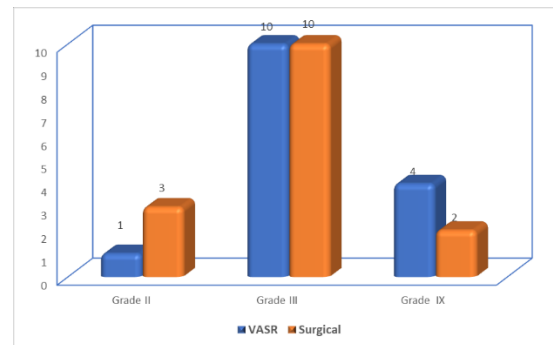


Fig 5: Distribution of Pre-operative grading between the studied groups.

Regarding post-operative grading, among the VASER group, 9 patients (60%) were grade I, and 6 patients (40%). While among the surgical group, 14 patients (93.3%) were grade I, and one patient (6.7%) was grade II. There was no statistically significant difference between the two studied groups as regards post-operative grading (p=0.08). (Table 5; Figure 6).

Among the surgical group, 11 out of 15 patients (73.3%) underwent face-lift technique and 4 out of

15 patients (26.7%) underwent submental technique. (Table 6; Figure 7).

Regarding the scar score, all patients in the VASER group achieved good score. While among the surgical group, 6 patients (40%) achieved good score, 5 patients (33.3%) achieved accepted score, 3 patients (20%) achieved poor to accepted score, and one patient (6.7%) achieved poor score.

There was a high statistically significant difference between the studied groups according to scar score (p=0.0007). (Table 7; Figure 8).

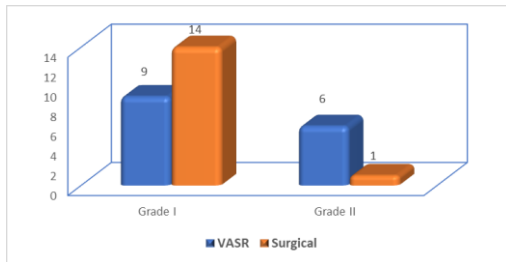


Fig 6: Distribution of Post-operative grading between the studied groups.

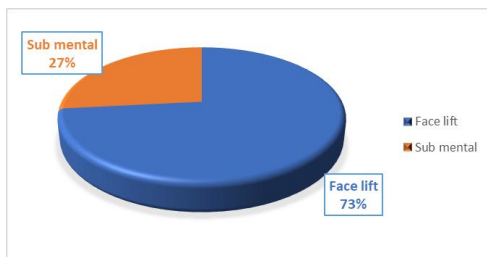


Fig 7: Distribution of technique used in Surgical group.

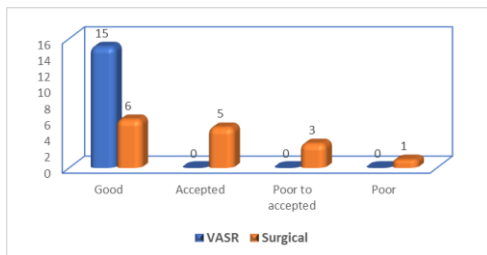

Fig 8: Distribution of Scar score between the studied groups.

Regarding patient acceptance, among the VASER group, 6 patients (40%) reported good score, 5 patients (33.3%) reported very good score, 4 patients (26.7%) reported fair score. While 10 patients (66.7%) reported very good score, 3 patients (20%) reported excellent score and 2 patients (13.3%) reported good score. There was a high statistically significant difference between the studied groups according to patient acceptance (p= 0.008). (Table 8; Figure 9).

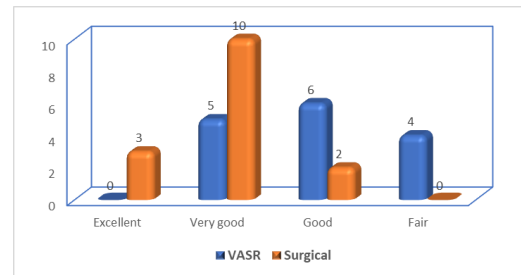


Fig 9: Distribution of patient acceptance between the studied groups.

The complications occurred in the studied groups were shown in (Table 9; Figure 10). The most common complications among the VASER group were neuropraxia in 4 patients (26.7%) and persistent skin laxity in 3 patients (20%). While the most common complications among the surgical group were scar deformity in 9 patients (60%) and neuropraxia in 2 patients (13.3%).

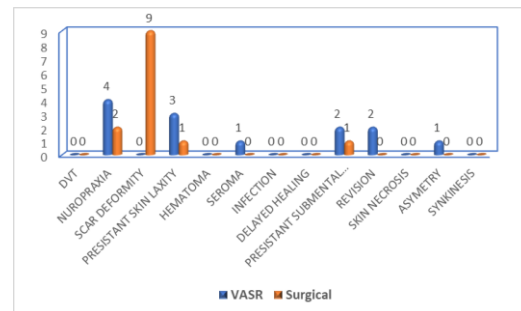


Fig 10: Distribution of complications between the studied groups.

	VASER (n=15)	Surgical (n=15)	Student t. test
Preoperative skin pinch test (Cm)			
Min. – Max.	1.3 – 2.5 cm	1.2 – 2.1 cm	T= -1.174 P= 0.251
Mean ± SD	1.85 ± 0.39	1.7 ± 0.29	
Median (IQR)	1.8 (1.5 – 2.0)	1.7 (1.5 – 2.0)	

Table 1: Comparison between the studied groups according to pre-operative skin pinch test.

	VASER (n=15)	Surgical (n=15)	Mann-Whitney test
Postoperative skin pinch test (Cm)			
Min. – Max.	0.3 – 0.6 cm	0.4 – 0.6 cm	W = 133 P= 0.383

Mean \pm SD	0.467 \pm 0.105	0.50 \pm 0.076
Median (IQR)	0.5 (0.4 – 0.55)	0.5 (0.45 – 0.55)

Table 2: Comparison between the studied groups according to post-operative skin pinch test.

	VASER (n=15)	Surgical (n=15)	Mann-Whitney test	
Operative time (minutes)				
Min. – Max.	50 – 110 min.	150 – 300 min.	W = 225	P < 0.0001*
Median	70 min.	240 min.		

Table 3: Comparison between the studied groups according to operative time.

	VASER (n= 15)		Surgical (n=15)		Fisher test
Pre- -operative grading					
	No.	(%)	No.	(%)	P = 0.489
Grade II	1	6.7%	3	20%	-
Grade III	10	66.7%	10	66.7%	
Grade IV	4	26.7%	2	13.3%	

Table 4: Comparison between the two studied groups according to pre--operative grading.

	VASER (n= 15)		Surgical (n=15)		Fisher test
Post-operative grading					
	No.	(%)	No.	(%)	P = 0.08
Grade I	9	60%	14	93.3%	-
Grade II	6	40%	1	6.7%	

Table 5: Comparison between the studied groups according to post-operative grading.

Technique	No.	(%)
Face-lift	11	73.3%
Submental	4	26.7%

Table 6: Distribution of technique used in Surgical group.

	VASER (n= 15)		Surgical (n=15)		Fisher test
Scar Score					
	No.	(%)	No.	(%)	P = 0.0007*
Good	15	100%	6	40%	
Accepted	0	0%	5	33.3%	
Poor to accepted	0	0%	3	20%	
Poor	0	0%	1	6.7%	

Table 7: Comparison between the studied groups according to Scar Score.

	VASER (n= 15)		Surgical (n=15)		Fisher test
Patient Acceptance					
	No.	(%)	No.	(%)	P = 0.008*
Excellent	0	0%	3	20%	-
Very good	5	33.3%	10	66.7%	
Good	6	40%	2	13.3%	
Fair	4	26.7%	0	0%	

Table 8: Comparison between the studied groups according to patient acceptance.

Complications	VASR (n= 15)		Surgical (n=15)		Fisher test
	No.	(%)	No.	(%)	
Dvt	0	0%	0	0%	- P = 0.002*
Nuropraxia	4	26.7%	2	13.3%	
Scar deformity	0	0%	9	60%	
Presistant skin laxity	3	20%	1	6.7%	
Hematoma	0	0%	0	0%	
Seroma	1	6.7%	0	0%	
Infection	0	0%	0	0%	
Delayed healing	0	0%	0	0%	
Presistant submental adiposity	2	13.3%	1	6.7%	
Revision	2	13.3%	0	0%	
Skin necrosis	0	0%	0	0%	
Asymetry	1	6.7%	0	0%	
Synkinesis	0	0%	0	0%	

Table 9: Comparison between the studied groups according to the complications.

DISCUSSION

Excess submental fat, also referred to as a "double chin," is a popular cosmetic concern among today's patients. There is already a plethora of novel non-invasive and minimally invasive treatments available for treating this traditionally tough to target anatomical location.¹

There is a paucity of clinical trials directed towards options for treating the aging neck. In terms of skin laxity particularly, the gold standard of treatment remains rhytidectomy or facelift.¹⁰

Rhytidectomy (facelift surgery) is a cosmetic rejuvenation procedure which removes extra saggy skin, reduces the appearance of wrinkles and marionette lines, and corrects facial adipose depletion or double chin. It is the seventh most popular cosmetic operation (with 126,713 operations done in USA in 2014) and the most prevalent aesthetic surgery in people over the age of 65.¹¹

The most of the patients in this study were obese or overweight. The VASER group had a higher mean BMI than the surgical group (31.2 ± 2.51 vs 30.67 ± 2.23 , respectively) with no reported statistically significant difference in BMI between the two groups.

Several studies have confirmed the current study's results that increasing BMI causes a relative broadening of the midface and lower face, and that people with poor body fat percentage possess a more angular face featuring moderately narrow cheeks as well as a pointy chin.^{12,13&14}

In addition, in the surgical approach, placement of the incision is a challenge. It is dictated by the method of surgery used. The surgery could range from Saylan's S-lift, purse-string facelift, minimal access cranial suspension lift, Brandy's modification of S-lift, short-scar purse-string facelift, anterior

cervicoplasty to single incision minimally invasive neck lift.^{15,16}

For isolated neck, rejuvenation procedure is reported to be the best.¹⁶ Although the submental incision is more easily concealed, the postauricular incision is more difficult to hide particularly in men, because their hair is usually short-cropped, making incisions in this area more hard to conceal. In addition, the lack of a postauricular incision may result in less pain than if one is present.¹⁷

In this study, the procedure of VASER assisted liposuction was no more time consuming compared to the conventional liposuction because the added emulsification and tightening time. the time for emulsification and tightening time not exceeded 3 or 4 minutes due to small area of liposuction and the emulsification and tightening was done in the same time. This added time was accepted by patients who had adequate information about the operation steps.

Besides, timesaving in the VASER technique due to shorter operation time is one of the main advantages.^{18,19} Similarly, we reported that the intraoperative time of VASER was significantly lower than the surgery ($P < 0.0001^*$).

In this advanced technology of VASER assisted liposuction, no need for skin ports, just antibiotic ointment was used as lubricant, without any complication of burn in site of canula entry.

To determine the efficacy of liposuction in the current study, the skin pinch test was measured before and after the operation immediately in both groups, it is a good indicator for amount of fat in sub mental area and for how much the liposuction is effective and also for symmetrical regularity, and skin laxity.

To avoid subdermal suction, a thin layer of fat (a few millimeters) has been left in situ below the dermis, resulting in an adipocutaneous flap. This has been performed for two reasons: (1) to avoid the deep dermal component from sticking directly to the muscular fascia beneath. This might result in ugly cord adhesions and bridles which might not be evident at rest but may be evident when the neck moves and during swallowing, necessitating additional corrective surgery like lipofilling; and (2) to protect the flaps from vascular (subdermal plexus) damage, which could result in both partial flap necrosis or the creation of a cutaneous pattern that resembles cutis marmorata.²⁰

UAL's (Ultrasound-assisted liposuction) safety is debatable. In one study of 250 consecutive UAL patients, three incidences of cutaneous necrosis (1.2%) and postoperative seromas were discovered (11.2%), based on this report and others.¹⁹

In our study no skin necrosis or postoperative seromas. With age, hypertrophy and/or ptosis of the submandibular salivary glands might occur. This contributes to an obtuse cervicomenal angle by creating submandibular fullness and an ill-defined mandibular border. Submental lipectomy can disclose gland prominence, which can be addressed by platysmarrhaphy. There are 2 cases with Submandibular salivary gland ptosis; one case in VASER assisted liposuction group and one case in surgery group in vertical face lift technique, but, the patient was satisfied.

Following neck liposuction, platysmal banding may become visible. Although rigorous preoperative evaluation and discussions of alternatives like platysmal plication reduce the danger, it does not fully remove it. Botulinum toxin in tiny doses may significantly enhance platysmal banding. Rod Rohrich et al.⁹ describe injecting 2.5 units of abotulinum toxin to treat platysmal banding. Resistant instances might necessitate platysma plication as a separate procedure.

Two cases in VASER assisted liposuction group was suffering from platysmal banding, which appeared post-operative, and one case treated by BOTOX injection, and another case lost.

In the surgical group, the platysma was addressed through platysmal plication in submental incision or lateral suspension of platysma in mastoid fascia with or without medial transection of band (if the lateral suspension is enough).

In the present study, the assessment of results was done through subjective evaluation (pre, post-operative photography of patients and patient satisfaction), objective evaluation (pre, post-operative skin pinch test and degree of cervicomenal angle or grading) and complications.

In the present study, evaluation of patient satisfaction and clinical effects were performed. Regarding the scar score, patients in the VASER group showed

significantly higher score than patients in the surgical group ($P = 0.007^*$). All patients in the VASER group achieved good score. While among the surgical group, 6 patients (40%) achieved good score, 5 patients (33.3%) achieved accepted score, 3 patients (20%) achieved poor to accepted score which treated by silicon sheet and CO2 fractional laser, and one patient (6.7%) achieved poor score which need scar revision. The scar score was mentioned by Parsa et al.²¹ is simple and specific to neck lift.

Regarding patient acceptance, patients in the surgical group showed significantly higher score than patients in the VASER group ($P = 0.008^*$). Among the VASER group, 6 patients (40%) reported good score, 5 patients (33.3%) reported very good score, 4 patients (26.7%) reported fair score. While in surgical group, 10 patients (66.7%) reported very good score, 3 patients (20%) reported excellent score and 2 patients (13.3%) reported good score.

The patient satisfaction survey was done between 3rd month and 6th month post-operative, some patient give us excellent impression on operation in 1st or 2nd month, but after 5th or 6th month, the patient downgrading the score especially in VASER group, this is due to appearance of some skin laxity after edema subside, or due to appear of platysmal band which was masked by fat, temporary marginal mandibular branch of facial nerve palsy or as a result of the patient ignoring the previous shape of their neck pre-operatively.

In the current study, the surgical group had significantly more complications than the VASER group ($P = 0.002^*$). The most frequent complications among the VASER group were neuropraxia in 4 patients (26.7%) and persistent skin laxity in 3 patients (20%). While the most common complications among the surgical group were scar deformity in 9 patients (60%) and neuropraxia in 2 patients (13.3%).

Neuropraxia of the facial nerve's marginal mandibular branch, was temporary, and recovery occurred within 3 weeks, one case in VASER group was suffered from moderate angle of moth deviation for 10 weeks, and the Neuropraxia resolved by medical treatment (vitamin b 12).

CONCLUSION

Surgical neck lifting is the best result, especially in old age however, VASER liposuction have a good result in young and middle age, especially in mild, moderate and some cases of sever lipodystrophy, the vaser liposuction is a good option for the patient who's afraid of the scar of surgery.

REFERENCES

1. Thomas WW and Bloom JD. Neck Contouring and Treatment of Submental Adiposity. *J Drugs Dermatol.* 2017;16(1):54-7.

2. Bhojwani A. Addressing the "Double Chin:" Trends in Submental Contouring. *Journal of Dermatology and Cosmetology*. 2016;1. (10):15406.
3. Alhaddad M, Zade J, Nabatian A, et al. Association Between Surgeon-Specific Features and Number of Stages, Flaps, and Grafts in Mohs Micrographic Surgery: A Retrospective Observational Study of 59 Early-, Mid-, and Advanced-Career Mohs Surgeons. *Dermatol Surg*. 2017;43(11):1358-62.
4. Fattahi T. Submental liposuction versus formal cervicoplasty: which one to choose? *J Oral Maxillofac Surg*. 2012;70(12):2854-8.
5. G. LaTrenta: Atlas of Aesthetic Face & Neck Surgery. Clodius Leo *European Journal of Plastic Surgery*. 2005;105.
6. Massignan F. Safety Evaluation of Vaser® in Body Contouring Improvement Liposuction. *Surgery Curr Res*. 2018;8(308):2161-1076.
7. Alam, M. Abdominal VASER LipoSelection Avoiding Abdominoplasty. *Biomedical Journal of Scientific & Technical Research*. 2018;6(10):2671.
8. Aleksandrovich IV. Correction of the Lower Third of the Face and Submental Area in Various Types of Aging with Laser-Assisted Liposuction. *Enhanced Liposuction - New Perspectives and Techniques*. 2021.
9. Rohrich RJ, Rios JL, Smith PD, et al. Neck rejuvenation revisited. *Plast Reconstr Surg*. 2006;118(5):1251-63.
10. Metzger KC, Crowley EL, Kadlubowska D, et al. Uncommon Adverse Effects of Deoxycholic Acid Injection for Submental Fullness: Beyond the Clinical Trials. *J Cutan Med Surg*. 2020;24(6):619-24.
11. Halepas, S., Weyman, D. and Ferneini, E. Complications in Minimally Invasive Facial Cosmetic Surgery. *Journal of Oral and Maxillofacial Surgery*. 2018. 76(10),44-5.
12. Ferrario VF, Dellavia C, Tartaglia GM, et al. Soft tissue facial morphology in obese adolescents: a three-dimensional noninvasive assessment. *Angle Orthod*. 2004;74(1):37-42.
13. Coetzee V, Chen J, Perrett DI, et al. Deciphering faces: quantifiable visual cues to weight. *Perception*. 2010;39(1):51-61.
14. Lee BJ, Do JH and Kim JY. A classification method of normal and overweight females based on facial features for automated medical applications. *J Biomed Biotechnol*. 2012; 2012:834578.
15. Bruneau S, Nguyen P, Foletti JM, et al. Neck rejuvenation by anterior cervicoplasty: an original technical modification. *J Plast Reconstr Aesthet Surg*. 2013;66(11):1627-8.
16. Kaplan JL. The Single Incision Minimally Invasive (SIMI) Neck Lift. *Plast Reconstr Surg Glob Open*. 2019;7(5):2208.
17. Balaji SM and Balaji P. Plication of Neck Strap Muscles and Platysma for Double Chin Correction - A Retrospective Study. *Ann Maxillofac Surg*. 2020; 10(2):417-21.
18. Di Giuseppe A, and Commons G. Facial Recontouring with Liposuction. In M. A. Shiffman & A. Di Giuseppe (Eds.), *Cosmetic Surgery: Art and Techniques* Berlin, Heidelberg: Springer Berlin Heidelberg, 2013; 461-6.
19. Grotting JC and Beckenstein MS. Cervicofacial rejuvenation using ultrasound-assisted lipectomy. *Plast Reconstr Surg*. 2001;107(3):847-55.
20. Innocenti A, Amodeo CA and Ciancio F. Wide-undermining neck liposuction: tips and tricks for good results. *Aesthetic plastic surgery*. 2014;38(4):662-9.
21. Parsa FD, Castel N and Parsa NN. A Modified, Direct Neck Lift Technique: The Cervical Wave-Plasty. *Arch Plast Surg*. 2016;43(2):181-8.