

Targeted Endovascular Therapy Combined with Angiographic Wound Blush as a Novel Predictor for Limb Salvage in Patients with Critical Limb Ischemia

Abdullah Al-Mallah,¹ MSc, Mohamed Abd El-Hamid,¹ MD, Mohamed Hamza,¹ MD.

* Corresponding Author:

Abdullah Al-Mallah

abdullah.al-mallah@azhar.edu.eg

Received for publication August 8, 2021; Accepted October 9, 2021; Published online October 9, 2021.

Copyright The Authors published by Al-Azhar University, Faculty of Medicine, Cairo, Egypt. Users have the right to read, download, copy, distribute, print, search, or link to the full texts of articles under the following conditions: Creative Commons Attribution-Share Alike 4.0 International Public License (CC BY-SA 4.0).

doi: 10.21608/aimj.2021.86163.1527.

¹Vascular Surgery Department, Faculty of Medicine, Al-Azhar University, Cairo, Egypt.

ABSTRACT

Background: Chronic threatening limb ischemia (CTLI) is a major medical problem affecting limbs, quality of life and survival. Angioplasty is considered as the first choice for treatment. Neither definite strategy was defined as the best option nor intraoperative endpoint for successful angioplasty for infragenicular vessels.

Aim of the study: to investigate angiosomal concept and wound blush in wound healing after infra-genicular angioplasty.

Patients and Methods: 40 patients with CTLI affecting the infra-genicular arteries. Patients were divided into two groups; Direct revascularization (DR) and Indirect Revascularization groups (This was done if the direct revascularization was not technically possible). According to post intervention wound blush, patients were categorized into WB-positive and WB-negative groups. Follow up was done on 1, 3, 6 and 12 months postoperatively.

Results: 60% (24/40) underwent DR, whereas 40% (16/40) underwent IR. ABPI was improved significantly postoperatively. For DR group, 14 (87.5%) patients had their wounds completely epithelialized (P=0.005) and overall limb salvage was 70% (P=0.03). For the IR group, six (54.5%) patients had limb salvage, two (28.57%) had major amputation. From the 40 endovascular interventions, 8 limbs showed positive WB and 32 showed negative WB. Limbs with positive WB healed in a significantly shorter duration (2.82±0.49 months) than did limbs with negative WB (3.2±0.63 months).

Conclusion: DR technique should be the first therapeutic choice for infragenicular angioplasty as it is associated with higher wound healing and limb salvage rates. Presence of wound blush post intervention is a good predictor of wound healing rate and time.

Keywords: Angioplasty, Infra-genicular, wound healing, wound blush.

Disclosure: The authors have no financial interest to declare in relation to the content of this article. The Article Processing Charge was paid for by the authors.

Authorship: All authors have a substantial contribution to the article.

INTRODUCTION

Chronic limb threatening ischemia is defined as low blood supply to a limb less than its metabolic demands at rest^{1,2}. It is clinically diagnosed as rest pain or pedal necrosis with appropriate documentation of circulatory impairment Fontaine stages III and IV³.

About 40% of CLI patients end in major amputation with its negative impact on patient quality of life. The primary aim of CLI revascularization is to improve wound healing, limb salvage, quality of life and also to prolong survival^{1,2}.

Therapeutic goals for chronic limb threatening ischemia include relief of symptoms and preservation of organs and tissues. Once the affected luminal diameter is compromised by 75% or more, the risk of limb loss becomes high. After this point, revascularization becomes necessary⁴.

PTA is the appropriate choice for Infrapopliteal occlusive disease; experience is increasing in this area⁵. Repeated PTA, unlike repeated surgical bypass operations, can be easily performed in case of restenosis^{6,7}.

The angiosome concept was firstly introduced by authors Taylor and Palmer in 1987⁸. Foot is divided into 6 areas (angiosomes), with independent artery for each. Clinical symptoms will appear in the area supplied by the target vessel due to lack of blood supply⁹. Nevertheless, this theory is still controversial in the absence of clues by convincing methods¹⁰.

Also, we need an intraoperative indicator for healing of ulcers. Wound blush was mentioned by few articles as a predictor for healing¹¹. Wound blush

(WB) means opacification of the ulcer area by contrast after angiography¹¹.

Skin perfusion pressure (SPP) has been associated with limb salvage rate. It indicated the flow of blood supply to the skin is adequate¹².

Accordingly, this thesis was conducted to investigate angiosomal concept in improving outcome of endovascular therapy and wound blush as an intraoperative predictor of healing.

Aim of this study was to investigate angiosomal concept in improving outcome of endovascular therapy and wound blush as an intraoperative predictor of healing in infra-genicular balloon angioplasty in cases of critical lower limb ischemia.

PATIENTS AND METHODS

The present study included 40 patients with limb threatening ischemia affecting the infra-genicular arteries. Patients admitted to the vascular surgery department, Al-Azhar University Hospitals and Nasr Insurance Hospital. Ethical consent was taken from all patients before inclusion in the study. This research was approved by ethical committee at Al-Azhar university, Faculty of medicine, Cairo, Egypt.

Inclusion criteria: ischemic lower limb ulcer or gangrene, Computerized Tomographic Angiography (CTA) evidence of significant isolated infra-genicular arterial occlusive disease.

Exclusion criteria: multi-level arterial lesions, Patients with creatinine >1.5 mg/dl, Acute on top of chronic ischemia, Asymptomatic patients., Burger's disease., non-disabling claudication patients., highly calcified lesions, Poor general condition (e.g., decompensated heart failure).

After consent, patients were subjected to History taking and Clinical examination for vital signs, General examination, Pulsation and Local examination. Hand-held Doppler examination and Ankle / Brachial index were also recorded. Routine lab investigations were done preoperatively. Computerized topographic arteriography (CTA) was done for all patents preoperatively.

Premedication included Clopidogrel bisulfate dose: (75 mg/day) and Aspirin dose: (100 mg/day) were initiated at least 5 days prior to endovascular interventions.

Endovascular Access was adopted via Ipsilateral anterograde approach. 4-Fr or 5-Fr diagnostic catheter was used for imaging of the trifurcation. This was obtained in A-P view and oblique views.

All infra-genicular lesions were dilated with pressure of 6-10 atm. for 1-3 minutes using low-profile balloons of 2-3 mm in diameter and length of 20-40 mm. Completion angiography was performed.

Heparin was continued for 24 to 48 h after the intervention. Clopidogrel was also continued for 3 months and aspirin for long term.

After angioplasty patients were divided into two groups according to angiosome concept: Direct revascularization group (DR): to which the artery supplied the affected angiosome was dilated. Indirect Revascularization group: to which the arteries rather than the artery supplied the affected angiosome were dilated (This was done if the direct revascularization was not technically possible).

Wound blush assessment: Evaluation of wound blush was done with different projection till having the best view with injection of 30 cc dye as near as possible popliteal artery (zone III).

Patients were categorized into two groups according to the angiography just after the angioplasty: WB-positive group: in which the site of the gangrenous or ulcerated area blush were achieved after intervention. WB-negative group: in which these angiographic results were not obtained.

Postoperative follow up was done on 1, 3, 6 and 12 months postoperatively. The target was relief of symptoms, patency rate, wound healing, ABPI, complications and mortality rate.

Data analyzed using SPSS version 25.0 statistical package (SPSS Inc., Chicago, IL, USA). Quantitative data expressed as mean and standard deviation (Mean \pm SD). Repeated measures ANOVA (T-test) were used to compare repeated measurements of patients' ankle pressure index by time followed by least significance difference post hoc test.

Quantitative data expressed as number and percentage and analyzed by Chi-square (X) test for association or trend when appropriate. Fishers' exact or Mont Carlo tests were used for small number or highly imbalanced table cells.

Nonparametric test (Mann Whitney) was used to compare continuous variables between the wound blush-positive and wound blush-negative groups. A p value <0.05 was considered to indicate a statistically significant difference.

RESULTS

40 patients who presented with CLI due to isolated infragenicular arterial occlusive diseases were included. Demographic data and comorbidities were shown in (Table 1).

The procedure time ranged from 45 min to 120 minutes with mean \pm SD (58.9 \pm 20 min.). The hospital stay ranged from 1 to 3 days with mean \pm SD (2.2 \pm 0.8 min.). Technical success was achieved in all patients. Patient who was difficult to be dilated by direct technique were shifted to indirect technique.

Technical complications occurred in six patients (12.5%), two of them (5%) developed groin hematoma which were managed conservatively, one patient (2.5%) developed infra-popliteal thrombosis which was managed by thrombolysis using Streptokinase (70.000-80.000 units). Two patients

(5%) developed flow limiting dissections which were managed by re-dilatation of the dissection flap, and one patient (2.5%) developed vessel perforation and treated by conservative measures.

Ankle Brachial Pressure Index (ABPI) evaluation was improved significantly and shown in (Table 2).

	Total (N=40)	%	DR (N=25)	%	IR (N=15)	%	P
Mean age	58.2		57.8		58.6		0.31
Sex ratio (M: F)	25:15	62.5:36.5%	19:6	76:24%	6:9	40:60%	0.022
Site of ischemic ulcer or gangrene							
Forefoot	29	72.50%	21	84.00%	8	53%	0.04
Heel	11	27.50%	4	16.00%	7	47%	
Associated comorbidities							
Diabetes	33	82.50%	21	84.00%	12	80.00%	0.26
Smoking	23	57.50%	18	72.00%	5	33.33%	0.017
Hypertension	35	87.50%	22	88.00%	13	86.67%	0.9
Dyslipidemia	19	47.50%	11	44.00%	8	53.33%	0.76
ischemic heart disease	11	27.50%	5	20.00%	6	40.00%	0.17
Stroke	7	17.50%	5	20.00%	2	13.33%	0.59
Previous amputations							
Previous major amputation	3	7.50%	2	8.00%	1	6.67%	0.87
Previous minor amputation	9	22.50%	5	20.00%	4	26.67%	0.62

Table 1: Patients' demographic data and comorbidities.

	Pre PTA	one month	3 months	6 months	1 year	P
Mean±S.D.	0.31±0.2	0.62±0.19	0.71±0.22	0.76±0.2	0.82±0.2	<0.001

Table 2: ABPI in the studied patients' groups pre- and post-operative.

ATA was the only distal runoff to the foot in 47.5% (19/40), posterior tibial artery (PTA) in 32.5% (13/40), the peroneal artery (PA) in the remaining 20% (8/40).

Details of intervention:

In the total group, 60% (24/40) underwent direct revascularization, whereas 40% (16/40) underwent IR. 22 patients had limb salvage, 15 of them had DR and seven had IR. six patients underwent major amputation, four of them were in the IR group and two were in the DR group. Details of findings were reported in (Table 3).

For DR group, 14 (87.5%) patients had their wounds completely epithelialized. Overall limb salvage was 70% (Table 4). Also (Figure 1) shows a case of posterior tibial artery repair (direct angioplasty).

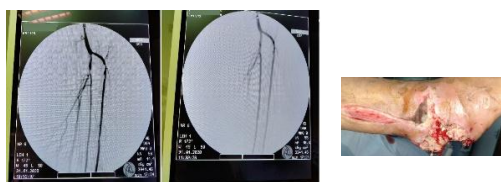

Fig 1: A case of anterior tibial artery repair (indirect angioplasty). Note: Heel ulcer was infected, and debridement was done.

For the IR group, six (54.5%) patients had limb salvage, two (28.57%) had major amputation, and five (31.25%) died, all secondary to cardiac causes (Table 5). (Figure 2) shows a case of PTA and PA repair (indirect angioplasty).

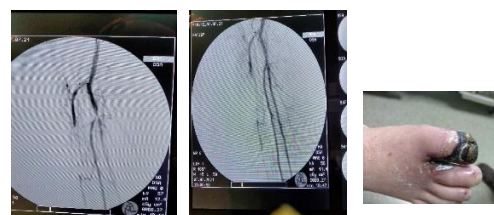


Fig 2: a case of PTA and PA repair (indirect angioplasty). We were unable to correct ATA lesion, so we turned to indirect angioplasty.

Illustrated points of difference between direct and indirect revascularization:

Direct revascularization, wound healing rate was higher significantly (P=0.005) (Table 6).

The limb salvage rate was also higher in the DR group than IR group at 12 months (P=0.03) (Table 7).

Post-interventional Wound blush findings:

From the 40 endovascular interventions, 8 limbs showed positive WB and 32 showed negative WB.

The kappa value was measured for interobserver agreement between operators for the WB (0.71) and for intraobserver agreement (0.70), which showed fair agreement.

As regards duration of wound healing, limbs with positive WB healed in a significantly shorter duration (2.82 ± 0.49 months) than did limbs with negative WB (3.2 ± 0.63 months).

Wound care was done daily by saline, povidone iodine and glycerin magnesia. This was done for all wounds to standardize wound care.

A significant relation between angiosome and WB was found. The limb salvage in positive WB was significantly higher in comparison to negative WB group (87.5% versus 18.75%) ($p=0.018$).

As regard the predictor of wound healing, WB was a significant predictor for wound healing. Positive WB has probability 4.3 time increase for wound healing in comparison to negative WB. Also, positive WB has probability 3.8 time decrease of amputation in comparison to negative WB (Figure 3)

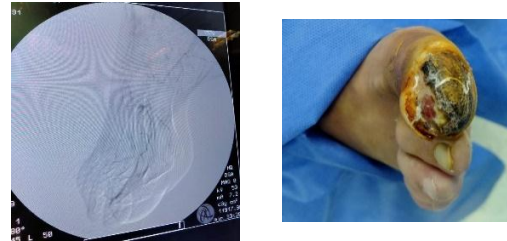


Fig 3: Wound blush at site of big toe ulcer and gangrene.

Results	1 month	%	3 months	%	6 months	%	12 months	%
Complete healing	5	14.29%	11	32.4%	14	48.28%	19	76.00%
Major amputation	3	7.89%	4	10.5%	6	17.14%	6	19.35%
Minor amputation	12	34.29%	12	35.3%	11	31.43%	15	60.00%
Limb salvage	35	92.11%	29	76.3%	24	68.57%	22	70.97%
Death	2	5.00%	2	5.0%	5	12.50%	9	34.62%

Table 3: Results for both groups.

Results	10month	%	3 months	%	6 months	%	12 months	%
Complete healing	4	17.39%	7	35.00%	11	50.00%	14	87.50%
Major amputation	2	8.70%	3	13.04%	4	18.18%	4	20.00%
Minor amputation	8	38.10%	9	45.00%	7	31.82%	11	55.00%
Limb salvage	22	95.65%	19	82.61%	16	72.73%	14	70.00%
Death	1	4.17%	1	4.17%	2	9.09%	4	20.00%

Table 4: Results obtained in the direct revascularization group.

Results	1 month	%	3 months	%	6 months	%	12 months	%
Complete healing	1	7.14%	2	14.29%	3	27.27%	5	71.43%
Major amputation	1	7.14%	1	7.14%	2	15.38%	2	28.57%
Minor amputation	4	28.57%	5	35.71%	4	36.36%	4	57.14%
Limb salvage	13	86.67%	13	86.67%	10	76.92%	6	54.55%
Death	1	6.67%	1	6.67%	3	23.08%	5	31.25%

Table 5: Results obtained at 1, 3, 6, and 12 months in the indirect revascularization group.

Complete healing	10 month	%	3 months	%	6 months	%	12 months	%
DR	4	17.39%	7	35.00%	11	50.00%	14	87.50%
IR	1	7.14%	2	14.29%	3	27.27%	5	71.43%
P-value	0.018		0.32		0.001		0.005	

Table 6: Wound healing in both groups.

Limb salvage	10 month	%	3 months	%	6 months	%	12 months	%
DR	22	95.65%	19	82.61%	16	72.73%	14	70.00%
IR	13	86.67%	13	86.67%	10	76.92%	6	54.55%
P-value	0.022		0.32		0.51		0.03	

Table 7: limb salvage in both groups.

DISCUSSION

The angiosome concept was firstly introduced by authors Taylor and Palmer in 1987. Foot is divided into 6 areas (angiosomes), with independent artery for each.^{8,13}

In this work, endovascular therapy was done to treat infragenicular arterial occlusive disease. Studies supporting the angiosome theory were Varela C et al.¹⁴, Iida O et al.¹⁵, Alexandrescu V et al.¹⁶, Blanes Ortí P et al.¹⁷, and Söderström M et al.¹⁸. A systematic review by Bosanquet et al., included 15 studies on 1,868 limbs and showed better wound healing rates and improved limb salvage rates¹⁹.

More recent updated systematic review confirmed these conclusions. 22 studies (4146 limbs) included. Time to wound healing, rate of wound healing and limb salvage were significantly better with DR compared with IR²⁰.

There are several reports supporting DR using endovascular techniques^{15,16,17}. From this study, the angiosome DR is superior to IR in terms of limb salvage and wound healing. We have turned into IR if DR was inaccessible or difficult.

Wound healing rates at 1, 3, and 6 months in DR versus IR were 7.9 versus 5%, 57.6 versus 12.5%, and 96.4 versus 83.3%, respectively ($P=0.021$).

This was matched with the results obtained in a prospective study by Kabra and colleagues, where 64 patients with CLI. DR was performed in 61% ($n=39$) and IR in 39% ($n=25$)¹³. Iida *et al.* reported 86% limb salvage rate in the DR group compared with 79% in the IR group ($p=0.3$)²¹.

Similar to current results, Alexandrescu *et al.*, documented how DR strategy in the treatment of diabetic patients with CLI provides better results in terms of limb salvage and wound healing than IR²².

Söderström *et al.* reported higher wound healing rate in DR ($P<0.001$); while Azuma *et al.* reported no difference ($P<0.185$)¹⁸.

According to Varela *et al.*, rate of wound healing in DR at 12 months was significantly higher than IR (92 vs. 73%; $P<0.01$) and limb salvage rate at 24 months was also higher (93 vs. 72%; $P<0.02$)¹⁴.

Analysis of our results revealed that DR concept may lead to significantly better rates of wound healing, and limb salvage, as Neville *et al.*, who found significant statistical difference in the rates of limb

salvage with DR ($P=0.03$), whereas wound healing was not different ($P=0.95$)²³.

Regarding wound blush, this study showed a relatively low number of patients with wound blush. Only 8 patients showed wound blush compared to 32 with negative wound blush. Statistical analysis of positive wound blush group showed significant higher wound healing rate and limb salvage.

These findings are in line with Utsunomiya studies in multiple publications.^{11, 24, 26}

Also, by searching literature, Xie *et al.*, confirmed the significant higher ulcer healing rate in positive wound blush group. Negative wound blush (OR =4.5, $P < 0.05$), was an independent risk factors of ulcer healing.²⁷

Also, Kang *et al.*, studied the grade of wound blush and its relation to wound healing. They reported that healing within 6 months was observed in 65.4% in blush positive Group compared with 10.7% in the negative group ($p<0.001$). Also, rates of amputation were 15.4% and 57.1%, respectively ($p=0.001$).²⁸ According to Andrew J.P. Klein, wound healing rate was higher with positive wound blush cases (79.6% vs. 46.5%; $p = 0.01$).²⁹

Some authors reported wound blush in non-ischemic cases as shown by Yashige *et al.*, in a patient with gout tophus.³⁰ So, this should be considered in future research regarding these limitations.

These results should be taken with caution due to relatively small sample size, few cases with positive wound blush. The fair agreement between operators about presence of wound blush could be resulted from patient slight movement on theatre or sometimes, presence of wound inflammation which causes hyperemia on wound site.

CONCLUSION

Endovascular therapy in CLI with infrapopliteal arterial disease is a safe and effective strategy, with good results for limb salvage and wound healing. DR technique should be the first choice for infragenicular angioplasty as it is associated with higher wound healing and limb salvage rates. Presence of wound blush post intervention is a good predictor of wound healing rate and time.

REFERENCES

1. Dick F, Diehm N, Galimanis A, et al. Surgical or endovascular revascularization in patients with critical limb ischemia: influence of diabetes mellitus on clinical outcome. *Journal of vascular surgery*. 2007;45(4):751-61.
2. Farber A. Chronic Limb-Threatening Ischemia. *New England Journal of Medicine*. 2018;379(2):171-80.
3. Nehler MR, Hiatt WR and Taylor Jr LM. Is revascularization and limb salvage always the best treatment for critical limb ischemia?. *Journal of vascular surgery*. 2003;37(3):704-8.
4. Shaker MSG. Role of Infragenicular Balloon Angioplasty in Treatment of Critical Lower Limb Ischemia in Diabetic Patients: *Minia University*; 2013.
5. Rosenfield K, Schainfeld R and Isner JM. Percutaneous revascularization in peripheral arterial disease. *Current Problems in Cardiology*. 1996;21(1):3-93.
6. Gray BH, Laird JR, Ansel GM, et al. Complex Endovascular Treatment for Critical Limb Ischemia in Poor Surgical Candidates: A Pilot Study. *Journal of Endovascular Therapy*. 2002;9(5):599-604.
7. Yousuf MT, Gouda MM, Herz-Allah AM, et al. Percutaneous transluminal angioplasty for isolated infrapopliteal arterial occlusive disease in diabetic patients with critical limb ischemia. *Journal of Medicine in Scientific Research*. 2020;3(3):207.
8. Taylor GI and Palmer JH. The vascular territories (angiosomes) of the body: experimental study and clinical applications. *British Journal of Plastic Surgery*. 1987;40(2):113-41.
9. Jongsma H, Bekken JA, Akkersdijk GP, et al. Angiosome-directed revascularization in patients with critical limb ischemia. *Journal of Vascular Surgery*. 2017;65(4):1208-19.
10. Ma J, Lai Z, Shao J, et al. Infrapopliteal endovascular intervention and the angiosome concept: intraoperative real-time assessment of foot regions' blood volume guides and improves direct revascularization. *European radiology*. 2021;31(4):2144-52.
11. Utsunomiya M, Nakamura M, Nakanishi M, et al. Impact of wound blush as an angiographic end point of endovascular therapy for patients with critical limb ischemia. *Journal of vascular surgery*. 2012;55(1):113-21.
12. Castronuovo Jr JJ, Adera HM, Smiell JM, et al. Skin perfusion pressure measurement is valuable in the diagnosis of critical limb ischemia. *Journal of vascular surgery*. 1997;26(4):629-37.
13. Kabra A, Suresh KR, Vivekanand V, et al. Outcomes of angiosome and non-angiosome targeted revascularization in critical lower limb ischemia. *Journal of Vascular Surgery*. 2013;57(1):44-9.
14. Varela C, Acín F, de Haro J, et al. The Role of Foot Collateral Vessels on Ulcer Healing and Limb Salvage After Successful Endovascular and Surgical Distal Procedures According to an Angiosome Model. *Vascular and endovascular surgery*. 2010;44(8):654-60.
15. Iida O, Nanto S, Uematsu M, et al. Importance of the angiosome concept for endovascular therapy in patients with critical limb ischemia. *Catheterization and Cardiovascular Interventions*. 2010;75(6):830-6.
16. Alexandrescu V and Hubermont G. Primary infragenicular angioplasty for diabetic neuroischemic foot ulcers following the angiosome distribution: a new paradigm for the vascular interventionist? *Diabetes, Metabolic Syndrome and Obesity: Targets and Therapy*. 2011:327.
17. Blanes Ortí P, Riera Vázquez R, Puigmacià Minguell R, et al. Revascularización percutánea de angiosomas específicos en isquemia crítica de la extremidad. *Angiología*. 2011;63(1):11-7.
18. Söderström M, Albäck A, Biancari F, et al. Angiosome-targeted infrapopliteal endovascular revascularization for treatment of diabetic foot ulcers. *Journal of Vascular Surgery*. 2013;57(2):427-35.
19. Bosanquet D, Glasbey J, Williams I, et al. Systematic review and meta-analysis of direct versus indirect angiosomal revascularisation of infrapopliteal arteries. *European Journal of Vascular and Endovascular Surgery*. 2014;48(1):88-97.
20. Dilaver N, Twine CP and Bosanquet DC. Editor's Choice—direct vs. indirect angiosomal revascularisation of infrapopliteal arteries, an updated systematic review and meta-analysis. *European Journal of Vascular and Endovascular Surgery*. 2018;56(6):834-48.
21. Iida O, Soga Y, Hirano K, , et al. Long-term results of direct and indirect endovascular revascularization based on the angiosome concept in patients with critical limb ischemia presenting with isolated below-the-knee lesions. *Journal of vascular surgery*. 2012;55(2):363-70.
22. Alexandrescu V-A, Hubermont G, Philips Y, et al. Selective Primary Angioplasty Following an Angiosome Model of Reperfusion in the Treatment of Wagner 1–4 Diabetic Foot Lesions: Practice in a Multidisciplinary Diabetic Limb Service. *Journal of Endovascular Therapy*. 2008;15(5):580-93.
23. Neville RF, Attinger CE, Bulan EJ, et al. Revascularization of a Specific Angiosome for Limb Salvage: Does the Target Artery Matter? *Annals of Vascular Surgery*. 2009;23(3):367-73.
24. Utsunomiya M, Takahara M, Iida O, et al. Wound blush obtainment is the most important

- angiographic endpoint for wound healing. *JACC: Cardiovascular Interventions*. 2017;10(2):188-94.
25. Utsunomiya M, Iida O, Yamauchi Y, et al. TCT-527 Obtainment of Wound Blush is The Most Important Angiographic Endpoint For Wound Healing. *Journal of the American College of Cardiology*. 2014;64(11):154.
 26. Utsunomiya M, Nakamura M, Nakanishi M, et al. Impact of wound blush sign as an endpoint of endovascular therapy for limb salvage in patients with critical limb ischemia. *Journal of the American College of Cardiology*. 2011;57(14):1961
 27. Xie H, Guo X, Lyu L, et al. Value of wound blush in predicting ulcer healing in patients with critical limb ischemia after endovascular revascularization. *International Journal of Surgery*. 2017;44(6):379-82
 28. Kang WY, Campia U, Bernardo NL, et al. Association Between Blush Grade and Wound Healing or Amputation in Critical Limb Ischemia. *Circulation*. 2015;132(3):16520.
 29. Klein AJ. Sailing the Murky Seas of Endovascular CLI Revascularization: Is Wound Blush Our Beacon?. *American College of Cardiology Foundation Washington, DC*; 2017.
 30. Yashige M, Kato T, Zen K, et al. Striking wound blush in the giant gout tophus detected immediately after endovascular revascularization. *Cardiovascular intervention and therapeutics*. 2019;35(3):316-7.