

Effect of Posterior Sub-Tenon Injection of Triamcinolone Acetonide as an Adjunct Therapy to Intravitreal Anti-Vascular Endothelial Growth Factor in The Management of Diabetic Macular Oedema

Ahmed Abdel-Mohsen Ali^{1,*} MSc.; Hosny Hassan Mohammad¹ MD.; Hassan Metwally Bayomy¹ MD.

* Corresponding Author:

Ahmed Abdel-Mohsen Ali
ahmedayoup2002@gmail.com

Received for publication April 8, 2020; Accepted September 10, 2020; Published online September 10, 2020.

Copyright 2020 The Authors published by Al-Azhar University, Faculty of Medicine, Cairo, Egypt. All rights reserved. This an open-access article distributed under the legal terms, where it is permissible to download and share the work provided it is properly cited. The work cannot be changed in any way or used commercially.

doi: 10.21608/aimj.2020.27481.1192

¹Ophthalmology Department, Al-Azhar University, Faculty of Medicine, Al-Azhar University, Cairo, Egypt.

ABSTRACT

Background: to monitor and compare the effect of posterior sub-tenon triamcinolone acetonide injection as an adjunct therapy to intravitreal ranibizumab injection on patients with diabetic macular oedema.

Aim of work: To assess the effect of combined intravitreal ranibizumab injection, and sub-tenon triamcinolone acetonide injection in the management of diabetic macular oedema.

Patient and Methods: Patients with diabetic retinopathy associated with DME (Central macular thickness over 300 um) which are randomly allocated into two groups. In group 1, three monthly doses (0.5 mg) of intravitreal ranibizumab are received. In group 2, the anti-VEGF injection was performed 3times monthly with the sub-tenon steroid injection [triamcinolone acetonide] during the 1st injection. All patients' best-corrected visual acuity (BCVA), IOP and CMT were followed up for six months.

Results: The combined treatment showed improved best-corrected visual acuity from baseline 0.15 ± 0.15 log MAR to 0.46 ± 0.19 log MAR ($p < 0.001$), which was statistically significant. In addition, there was decreased CMT from baseline 584.4 ± 120.28 to 235.94 ± 27.49 , which was highly statistically significant ($p > 0.001$). When comparing the combination treatment with the anti-VEGF treatment alone, recovery of BCVA and CMT was statistically significant ($p < 0.001$).

Conclusion: sub-tenon triamcinolone addition to the routine anti-VEGF therapy is an effective method for the treatment of diabetic macular oedema not only in rapid and great improvement but also in decreased frequent injections.

Keywords: Macular edema; Ranibizumab; Combined injection; subtenon triamcinolone.

Disclosure: The authors have no financial interest to declare in relation to the content of this article. The Article Processing Charge was paid for by the authors.

Authorship: All authors have a substantial contribution to the article.

INTRODUCTION

Diabetic macular oedema (DME) is one of the main causes of visual deterioration in patients with DM.¹ The Early Treatment Diabetic Retinopathy Study has suggested that grid laser photocoagulation for clinically significant macular oedema effectively decreased the incidence of moderate visual loss.

Later studies demonstrated that grid/ laser photocoagulation might cause decreased vision because of a progressive macular scar and subretinal fibrosis.² Focal/grid laser photocoagulation has considered the main treatment for diabetic macular oedema (DME) within the last 25 years. However, their results are limited in patients with DME caused by the extensive breakdown of the inner blood-retinal barrier.^{3,4} this has driven many investigators to look for alternative treatments for the management of DME. Treatment modalities for DME today are increasing in number. The efficacy of intravitreal

injection of anti vascular endothelial growth factor (anti-VEGF),⁵ intravitreal and sub-Tenon injection of triamcinolone acetonide (STTA),⁴ intravitreal sustained release dexamethasone implant,⁶ and also combined therapies,⁷ for DME are reported. combination of these therapies that consider different pathways of this multifactorial disease offers better results. By increasing the efficacy with additive effects and decreasing the therapy time and thus the costs, combination therapies may provide advantage both for the patients and physicians. In our study, we tried to assess the efficacy and safety of combined posterior STTA and intravitreal ranibizumab (IVR) therapy in patients with diabetic macular oedema (DME).

PATIENT AND MATERIALS

A prospective interventional comparative clinical trial conducted at Al-Azhar University Hospitals (Cairo, Egypt) from January 2018 to August 2019

and were followed-up for 6 months. The study included two groups; each included 25 eyes, all of which had type II diabetes mellitus with CSME according to the Early Treatment Diabetic Retinopathy Study (ETDRS) criteria. Patients were included if they clinically and angiographically (FFA) diagnosed as DME and have a central foveal thickness (CFT) greater than 250 μm on optical coherence tomography (OCT).

Exclusion criteria: were significant media opacity preventing retinal view, presence of traction on the macula evidenced by OCT, previous ocular surgery, history of previous laser photocoagulation, IV or PSTI of TA, history of uveitis attacks, any chorioretinal disease (other than diabetic retinopathy), glaucoma or ocular hypertension, diabetic papillopathy or ischemic maculopathy, and contraindications for ranibizumab or TA.

The systemic status of all patients was controlled. Each patient ophthalmologically examined briefly at baseline and at every follow-up visit, this included best-corrected visual acuity (BCVA), intraocular pressure (IOP) measurement by the Goldman applanation tonometer, and slit-lamp biomicroscopy with +90D noncontact lens.

Fundus fluorescein angiography (using IMAGE net 2000, Topcon TRC50IX; Topcon Corporation, Tokyo, Japan) was obtained at baseline for all patients and was repeated at follow-up visits if it was necessary for some patients. OCT was performed for all patients during preinjection and post injections follow-up visits to determine the CMT using spectral-domain OCT (Spectralis; Heidelberg Engineering, Germany). The Auto Rescan function of Spectralis OCT allows the repetition of follow-up scans for every patient.

Surgical procedures: The first group underwent 3 intravitreal injections (one-month interval) of 0.3mg Ranibizumab delivered in 0.05ml (Lucentis®, Genentech, Inc., South San Francisco, CA), While the second group underwent the same injections but combined during the 1st injection with posterior sub-tenon (PST) injection of 40 mg/ml Triamcinolone acetonide (Kenacort -A® Bristol-Myers Squibb Company New York – Cairo). Under standard aseptic techniques in the ophthalmic surgical theatre, A volume of 0.05 ml containing 0.3mg Ranibizumab was injected inside the vitreous cavity through pars plana 3.5–4mm posterior to the limbus using a sterile 30Gneedle in the inferotemporal quadrant. For posterior sub-tenon injection, Following disinfection and draping, supero-temporal or infero-nasal subconjunctival anaesthesia (2% lidocaine); a small conjunctival and Tenon's incision (7 mm posterior and either supero-temporal or infero-nasal to the limbus) was made to bare sclera. Using a curved blunt cannula (NAGATA® sub-tenon canula), the medication was infused in the posterior

juxta-scleral space. Afterwards, the surgical incision was cauterized, and topical antibiotic was instilled.

Follow-up: All patients underwent ophthalmic examination on days 1 and 7 post injections, to assess injection-related complications such as anterior chamber reaction or IOP rise, etc. Follow-up was performed regularly by determining the BCVA, IOP measurement, and fundus biomicroscopy. Anatomical (CMT) and functional (BCVA) outcomes were evaluated monthly using spectral-domain OCT and visual acuity chart, respectively.

Statistical analysis: Statistical analyses were performed by the use of SPSS software of Windows (version 15; SPSS Inc., Chicago, Illinois, The USA). Preinjection and post-injection measurements at 1st, 3rd and 6th months for all variables were tested by the paired sample t-test and AnOVA test. All values are expressed as MD \pm SD. P-values less than 0.05 were accepted as significant.

Ethical approval: The study was accepted by the Ethics Board of Al-Azhar University. Informed written consent was obtained from every patient before being included in the study.

RESULTS

Twenty five eyes of 20 patients (11 females and 9 males) were enrolled in group 1 (intravitreal ranibizumab injection), 25 eyes of 24 patients (14 females and 10 males) were enrolled in group 2 (posterior sub-tenon TA injection with intravitreal ranibizumab injection). The ages in group 1 ranged from 56 to 67 years 62.94 ± 4.92 (mean + SD), while the ages in group 2 ranged from 58 to 66 years 61.62 ± 4.60 (mean + SD). There was not a statistically significant difference in both study groups concerning age, gender, duration and status of diabetes.

The mean preoperative CMT of the combined group (IVRI+PSTA) (group 2) was $584.4 \mu \pm 120.28 \mu$, higher than mean preoperative CMT of the control group (group 1) $422.32 \mu \pm 114.45 \mu$. At one-month post-injection, group 2 had reached a CMT of $365.16 \pm 68 \mu$, showing an improvement of 37.5% from baseline. The group 1 had reached $359.2 \pm 96.6 \mu$ showing an improvement of 14.9% from baseline. But the absolute CMT is close and insignificant ($p=0.8$) when compared, with even a lower CMT in the group 1. At the next visits, the statistical significance remained, with ($p \leq 0.000$) at 3rd and 6th months. So, the clinical difference was significant, with a CMT of $253.28 \pm 37.6 \mu$ and $288.64 \pm 71.99 \mu$ at 3rd month ($p=0.034$) and finally $235.94 \pm 27.49 \mu$ and $305.24 \pm 82.5 \mu$ at 6th months ($p \leq 0.000$) in the group 2 and group 1 respectively (Figure 1&2 and table 1). There was recurrent and residual oedema in 8 patients (32%) in group 1, While in group 2; only 2 cases (8%) with residual oedema mostly due to drug reflux.

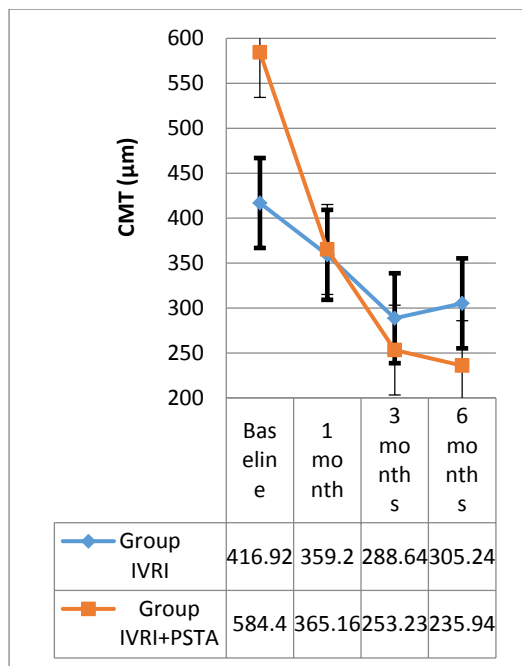


Fig. 1: This graph is showing comparison between both groups in CMT over follow up period. Data are presented as mean deviation

(µm micrometer, CMT central macular thickness, IVRI intra vitreal ranibizumab injection, PSTA posterior subtenon triamcinolone acetonid).

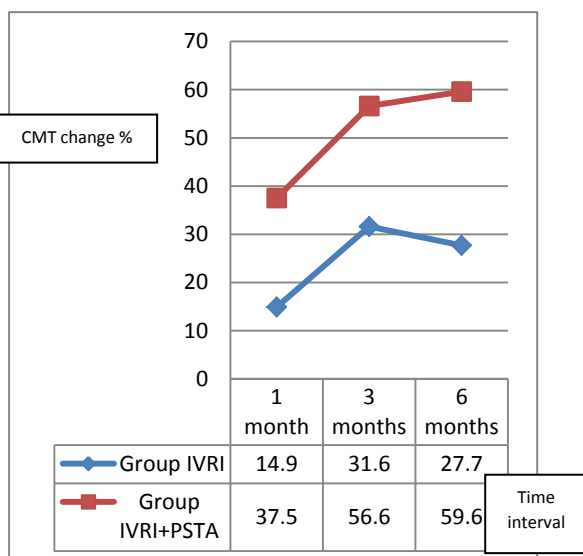


Fig. 2: This graph is showing a comparison in percentage change of CMT over the follow-up period between both groups.

Data are presented as mean deviation

(CMT central macular thickness, IVRI intra vitreal ranibizumab injection, PSTA posterior subtenon triamcinolone acetonid).

CMT (µm)	IVRI (MD±SD)	IVRI+PSTA (MD±SD)	t-test	p-value
Baseline	422.32±114.45	584.4±120.28	5.0	> 0.001
1 month	359.2±96.6	365.16±68	0.25	0.8
3 months	288.64±71.99	253.28±37.6	2.17	0.034
6 months	305.24±82.5	235.94±27.49	3.98	> 0.001
F-test	9.9	120.9		
p-value	>0.001	>0.001		

Table 1: This table is showing mean and Standard deviations of CMT of studied groups over the follow up period.

Data are presented as mean ±SD

(µm micrometer, CMT central macular thickness, IVRI intra vitreal ranibizumab injection, PSTA posterior subtenon triamcinolone acetonid, MD mean deviation, SD standard deviation).

The mean BCVA prior to injection was worse in the combined group (group 2) (0.15±0.15) than the IVRI only group (group 1) (0.21±0.15). At the 1st month post-injection it had improved to 0.28 and 0.29 respectively, the difference being statically insignificant between the two groups (P=0.93). At 3rd months it was 0.41 in the combined group (group 2), and 0.36 in the IVRI only group (group 1) with the difference in between the two groups is insignificant (P=0.08). At the last follow-up visit it was 0.46 in the combined group (group 2), and 0.37 in the PSTTA only group (group 1) and again the difference in between is insignificant (P=0.1) this insignificance is due to the starting difference in MD of BCVA in between both groups. The BCVA is significantly improved in both groups during the follow-up period being more in the combined group (86.7%-33.3%, 173.3%-71.4% and 206.7%-76.1% group 2 and group 1 at the 1st, 3rd and 6th month respectively) these data is shown in figure 3&4 and table 2.

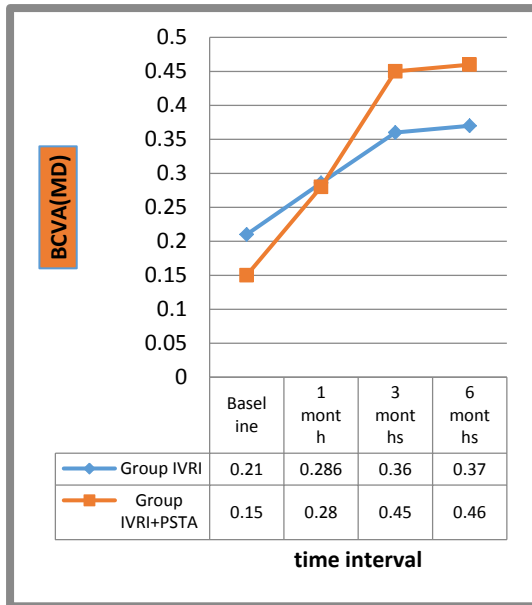


Fig. 3: This Graph is showing comparison between both groups in BCVA over the follow up period.

Data are presented as mean deviation. (BCVA best corrected visual acuity, IVRI intra vitreal ranibizumab injection, PSTA posterior subtenon triamcinolone acetamid)

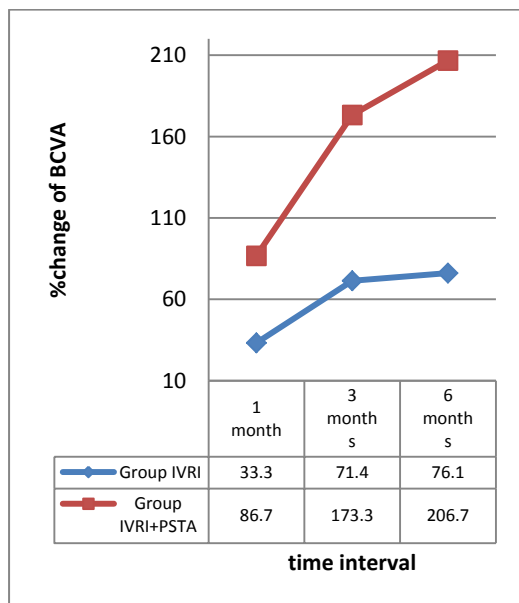


Fig. 4: This graph is showing a comparison in percentage change of BCVA over the follow-up period between both groups.

Data are presented as number (%) (BCVA best corrected visual acuity, IVRI intra vitreal ranibizumab injection, PSTA posterior subtenon triamcinolone acetamid)

BCVA	IVRI (MD±SD)	IVRI+PSTA (MD±SD)	t- test	p- value
Baseline	0.21±0.15	0.15±0.15	1.42	0.16
1 month	0.286±0.16	0.28±0.14	0.08	0.93
3 months	0.36±0.16	0.41±0.18	1.76	0.08
6 months	0.37±0.16	0.46±0.19	1.64	0.10
F-test	5.67	18.9		
p-value	0.0013	>0.001		

Table 2:Table showing mean and Standard deviations of BCVA of studied groups over the follow up period.

Data are presented as mean ±SD (µm micrometer, BCVA best corrected visual acuity, IVRI intra vitreal ranibizumab injection, PSTA posterior subtenon triamcinolone acetamid, MD mean deviation, SD standard deviatin).

Comparing the IOP of both groups in our study; mean IOP of both groups over the follow up period are shown in (Figure 5), Four patients (16%) showed a mild increase in IOP after injection during the first month which was transient and well-controlled by only one anti-glaucoma drug, and this is mostly due to steroid responders.

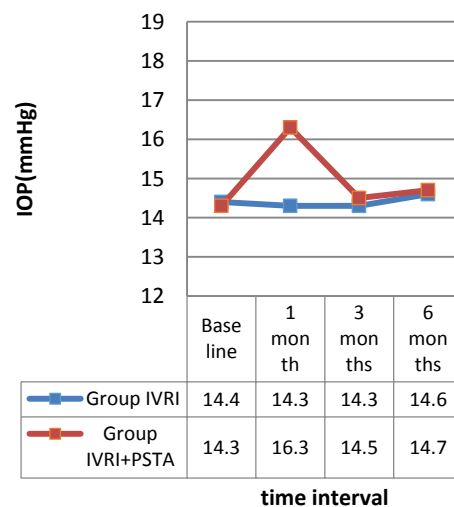


Fig. 5: This graph is showing a comparison between both groups in IOP over the follow-up period.

Data presented as mean deviation. (IOP intra ocular pressure, IVRI intra vitreal ranibizumab injection, PSTA posterior subtenon triamcinolone acetamid).

DISCUSSION

Diabetic macular oedema (DME) is the fundamental driver of dynamic lessening of vision in diabetic retinopathy patients that may occur at any stage of the retinopathy.⁹ Many factors are involved in the pathogenic process of DME; so, many alternatives are

needed to be suggested for the management of these patients either surgical or pharmacologic.¹⁰ Monotherapies are often not effective enough to well treat DME.¹¹ The roles of inflammatory mediators and VEGF in DME have been proved.¹² Anti-VEGF drugs can decrease the concentration of free VEGF but do not change the concentrations of other pro-inflammatory molecules.¹³ Combining corticosteroids with anti-VEGF drugs may produce the greatest possible suppression of vascular permeability.¹⁴ However, the use of intravitreal triamcinolone injection had been linked to the development of many complications.¹⁵ The PSTI of TA had a comparable effect with the IV TA and showed a lower risk of these complications.¹⁶

The underlying rationale for using sub-Tenon's capsule injection of TA for DME is that, apart from its safety, it also can penetrate the sclera and diffuse into the vitreous cavity.¹⁷ Bakri and Kaiser¹⁸ evaluated the role of PSTI of TA in improving visual acuity in patients with refractory DME. They found significant improvement in visual acuity at 1st month, which was maintained till 12 months. Therefore, PSTI of TA may be offered as a good alternative for the treatment of diffuse DME.¹⁶

The outcome of the present study revealed that combined IV ranibizumab with PSTI of TA was effective for the management of DME in terms of decreasing CMT and improving BCVA. This combined treatment protocol decreased CMT effectively below 300 μm in 24 eyes (96%) and provided improvement of visual acuity in all eyes (100%). The combined injection also greatly decreased the need for frequent injections as there was recurrent and residual oedema in 8 patients (32%) in group 1, While in group 2; only 2 cases (8%) with residual oedema mostly due to drug reflux. The improvement in the anatomical (CMT) and functional (BCVA) outcomes in the present study may be attributed to patients' selection criteria including the exclusion of ischemic DME cases and absent history of previous laser or ocular surgeries before enrollment.

In the present study, No eyes developed rise in IOP that necessitated anti-glaucoma drugs for long time during the follow-up period. Only one eye developed nuclear cataract at the end of the study (4%) and undergone phacoemulsification. Kim et al.¹⁹ reported that combined therapy with IV bevacizumab injection and PSTI-TA (4.0 mg) produced better clinical outcomes, especially at 1st month after injection compared with single injections of each one of them. Ahmadiet al.²⁰ compared IV bevacizumab with or without IV TA in DME and found that the addition of TA induced earlier visual improvement. Aly and Tag Eldin reported that combined IV bevacizumab with PSTI-TA was effective for the management of persistent DME in terms of decreasing CMT and improving BCVA.²¹

As regards the effect on IOP, Our results are nearly similar to that of Abdelkader SA Et al. study

that revealed that there was no critical difference between the two groups in terms of IOP increase before injection and at 3 months follow up. However, there was a significant difference between the two groups after 1 month follow up.²² Our results are also nearly similar to that of Ercalik NY et al. study, 5.2% of the eyes developed moderate IOP elevation in the combined group.²³

Limitations of our study include the relatively small number of enrolled patients and the short follow-up time. Therefore, further, long-term studies on a larger number of patients are required to confirm the long-term efficacy and safety of this combined treatment as a treatment option for DME.

CONCLUSION

The results of the present study show that adding PSTI-TA to IV ranibizumab has a great role in the treatment of DME not only in improving BCVA and decreasing CMT but also in minimizing the number of frequent injections when compared to anti-VEGF treatment alone, so the cost will be cheaper.

REFERENCES

1. Al Rasheed S and Arevalo JF. Combined therapy for diabetic macular oedema. *Middle East Afr J Ophthalmol* 2013; 20:315–20.
2. Aksoy S, Yilmaz G, Akkoyun I, et al. Comparison of intravitreal bevacizumab and triamcinolone acetonide therapies for diffuse diabetic macular oedema. *Int J Ophthalmol* 2015; 8:550–5.
3. Diabetic Retinopathy Clinical Research Network (DRCR .net). Three-year follow-up of a randomized trial comparing focal/grid photocoagulation and intravitreal triamcinolone for diabetic macular oedema. *Arch. Ophthalmol.*, 2009;127: 245–51.
4. Diabetic Retinopathy Clinical Research Network. Randomized trial evaluating ranibizumab plus prompt or deferred laser or triamcinolone plus prompt laser for diabetic macular oedema. *Ophthalmology*. 2010;117:1064–77.
5. Massin, P., Bandello, F., Garweg J.G., et al. Safety and efficacy of ranibizumab in diabetic macular oedema (RESOLVE Study): a 12-month, randomized, controlled, double-masked, multicenter phase II study. *Diabetes. Care*. 2010;33:2399–405.
6. Cellini, M., Pazzaglia, A., Zamparini, E., et al. Intravitreal vs sub-tenon triamcinolone acetonide for the treatment of diabetic cystoid macular oedema. *BMC. Ophthalmol.*, 2008;8:5.

7. Haller, J.A., Kuppermann BD, Blumenkranz, M.S., et al. Dexamethasone DDS Phase II Study Group. Randomized controlled trial of an intravitreal dexamethasone drug delivery system in patients with diabetic macular oedema. *Arch. Ophthalmol.*, 2010;128:289–96.
8. Chan CK, Lai TY, Mohamed S, et al. Combined high-dose sub-tenon triamcinolone, intravitreal bevacizumab, and laser photocoagulation for refractory diabetic macular oedema: a pilot study. *Retina* 2012; 32:672–8.
9. Cellini M, Pazzaglia A, Leonetti P, et al. Intra vitreal versus sub-tenon triamcinolone acetonide for the treatment of diabetic cystoid macular oedema. *BMC Ophthalmol* 2008; 8:5.
10. Faghihi H, Roohipoor R, Mohammadi SF, et al. Intravitreal bevacizumab versus combined bevacizumab-triamcinolone versus macular laser photocoagulation in diabetic macular oedema. *Eur J Ophthalmol* 2008; 18: 941–8.
11. Zur D and Loewenstein A. Combination therapy for diabetic macular oedema. *J Ophthalmol* 2012; 2012:484612.
12. Cellini M, Balducci N, Strobbe E, et al. Subtenon injection of natural leukocyte interferon α -2a in diabetic macular oedema: a case report. *BMC Ophthalmol* 2013; 13:63.
13. Maturi RK, Bleau L, Saunders J, et al. A 12-month, single-masked, randomized controlled study of eyes with persistent diabetic macular oedema after multiple anti-VEGF injections to assess the efficacy of the dexamethasone-delayed delivery system as an adjunct to bevacizumab compared with continued bevacizumab monotherapy. *Retina* 2015; 35:1604–14.
14. Kriechbaum K, Prager S, Mylonas G, et al. Intravitreal bevacizumab (Avastin) versus triamcinolone (Volon A) for treatment of diabetic macular oedema: one-year results. *Eye (Lond)* 2014; 28:9–15.
15. Kim MW, Moon H, Yang SJ, et al. Effect of posterior sub-tenon triamcinolone acetonide injection on diabetic macular oedema refractory to intravitreal bevacizumab injection. *Korean J Ophthalmol* 2016; 30:25–31.
16. Choi YJ, Oh IK, Oh JR, et al. Intravitreal versus posterior sub-tenon injection of triamcinolone acetonide for diabetic macular oedema. *Korean J Ophthalmol*, 2006; 20:205–9.
17. Lee SJ, Kim ES, Geroski DH, et al. Pharmacokinetics of intraocular drug delivery of Oregon Green 488-labelled triamcinolone by sub-tenon injection using ocular fluorophotometry in rabbit eyes. *Invest Ophthalmol Vis Sci* 2008; 49:4506–14.
18. Bakri SJ and Kaiser PK. Posterior sub-tenon triamcinolone acetonide for refractory diabetic macular oedema. *Am J Ophthalmol* 2005; 139:290–4.
19. Kim HD, Kang KD, Choi KS, et al. Combined therapy with intravitreal bevacizumab and posterior sub-tenon triamcinolone acetonide injection in diabetic macular oedema. *Acta Ophthalmol* 2014; 92:e589–90.
20. Ahmadi H, Ramezani A, Shoeibi N, et al. Intravitreal bevacizumab with or without triamcinolone for refractory diabetic macular oedema: a placebo-controlled, randomized clinical trial. *Graefes Arch Clin Exp Ophthalmol.*, 2008; 246:483–9.
21. Aly MM. and Tag Eldin AM. Combined intravitreal -posterior sub bevacizumab and Tenon's triamcinolone acetonide injections for persistent diabetic macular oedema. *Delta J Ophthalmol.* 153-2017:18:149
22. Abdelkader SA., Abdelhamid N. and Bahnassy M. Evaluation of The Effect of Combined Intra-Vitreal Ranibizumab Injection and Sub-Tenon Triamcinolone Acetonide Injection in The Management of Diabetic Macular Edema. *The Egyptian Journal of Hospital Medicine.* 2019;77:4815-9.
23. Ercalik NY, Yenere NM, Imamoglu S, et al. Combined -Sub Intravitreal Ranibizumab and Tenon Injection of Triamcinolone for the Treatment of Diabetic Macular Edema with Retinal Detachment. *J of OcularPharmacology and P Therapeutics.* 2016;32:4