

Study of the Effect of Prenatal Administration of Pregabalin on Cerebellar Cortex of Albino Rat's Offspring and the Possible Protective Role of Folic Acid

Moustafa Rizk Magar^{1,*} MSc, Mohamed Mohamed Ebada² MD, Moustafa Al-Sayed El-Gizawy² MD and Hamdino Mohamed Attia MD¹

* Corresponding Author:

Moustafa Rizk Magar

magarmostafa@gmail.com

Received for publication March 20, 2020; accepted July 4, 2020; published online July 4, 2020.

Copyright 2020 The Authors published by Al-Azhar University, Faculty of Medicine, Cairo, Egypt. All rights reserved. This an open-access article distributed under the legal terms, where it is permissible to download and share the work provided it is properly cited. The work cannot be changed in any way or used commercially.

doi: 10.21608/aimj.2020.29636.1220

¹Anatomy and Embryology Department, Faculty of Medicine, Al-Azhar University, Demietta, Egypt.

²Anatomy and Embryology Department, Faculty of Medicine, Al-Azhar University, Cairo, Egypt.

ABSTRACT

Background: Anti-epileptic drugs have harmful effects on nervous system development. Pregabalin was approved in 2004 as new anti-epileptic drugs. Supplementation of folic acid during pregnancy is associated with a lower incidence of developmental problems in the nervous system.

Objective (Aim): Assessment of the effects of prenatal administration of pregabalin on the cerebellar cortex of albino rat's offspring, and evaluation of folic acid's protective potential.

Material and methods: 24 pregnant albino rats were divided equally into group I, group II and group III. From gestational day one until birth, Pregabalin (80 mg/kg body weight/day) was given to group I, pregabalin (80 mg/kg body weight/day) and folic acid (400 µg/kg body weight/day) was given to Group III and no medications were given to group I. At the age of two and four weeks, 30 offspring born to the experimental groups were sacrificed (5 offspring from each group for each age). Specimens were taken from the cerebellar cortices of rat's offspring and were prepared for histological, immunohistochemical, and histomorphometric studies.

Results: The cerebellar cortex of the offspring of group II showed disrupted architecture with marked degenerative changes especially in Purkinje cells. Degeneration of the axons with depletion of myelin sheath was detected. The cerebellar cortex of the offspring of group III showed restoration of the normal architecture with an improvement of the degenerative changes.

Conclusions: Administration of Pregabalin during pregnancy has neurotoxic effects on the developing cerebellar cortex of albino rat's offspring. Also, the administration of folic acid alongside Pregabalin can reduce these neurotoxic effects.

Keywords: Pregabalin; Cerebellar cortex; Albino rat; Folic acid.

Authorship: All authors have a substantial contribution to the article.

Disclosure: The authors have no financial interest to declare in relation to the content of this article. The Article Processing Charge was paid for by the authors.

INTRODUCTION

The incidence of congenital malformations has increased because of the use of traditional anti-epileptic drugs during gestation (e.g., valproate, phenytoin, carbamazepine, and phenobarbital). Thus, it is necessary to find new safer drugs for the mother and the fetus to lower the incidence of these complications. This may need adequate clinical and experimental studies.¹

Pregabalin is the latest compound that joins the list of approved new AEDs. The European Commission granted Pfizer Company the approval for pregabalin in July 2004 for the treatment of variable types of peripheral neuropathic pain and in the same year, it was approved as adjunctive therapy for epilepsy by the American Food and Drug Administration (FDA).²

It has been shown that pregabalin can cross easily the placenta and the blood-brain barrier in rats, mice, and

monkeys. Therefore, pregabalin is an important drug that can influence the development of the nervous system after birth.³

The cerebellum of mammals has very interesting histological events during the nervous system development. Therefore, the cerebellum is an ideal model for studying many aspects of neural development, because each stage of its development has a distinct morphology and special histological features with different types of cells. As well as the process of cerebellar development is not complete during gestation only, but also, continues after birth.⁴

Pregabalin has been shown to have harmful effects on the developing cerebellum when given in higher doses. It causes loss of cellular components and

distortion of the cerebellar cortical layers that may affect the physiological functions of the cerebellum.⁵ Investigations showed that the incidence of malformations of the nervous system and musculoskeletal system has decreased with supplementation of folic acid during gestation, while folic acid deficiency during gestation was associated with a wide spectrum of congenital malformations.⁶ Therefore, this study was carried out to investigate the folic acid's protective potential against the postnatal histological changes in the cerebellar cortex of albino rat's offspring due to pregabalin administration during gestation.

MATERIAL AND METHODS

Pregabalin capsules 300 mg were supplied from Pfizer-Egypt Company. In 37.5 ml of distilled water, 10 capsules of pregabalin 300 mg were dispersed to produce a suspension containing 80 mg of pregabalin/ml of distilled water. Folic acid tablets 500 µg were supplied from MEPACO-MEDIFOOD Company, Egypt, Cairo. In 25 ml of distilled water, 5 tablets of folic acid 500 µg were dissolved to produce a suspension containing 100 µg of folic acid / 1 ml of distilled water.

Sixty-six adult albino rats (forty-four female and twenty-two male albino rats) were selected for this study with their weight ranged between 200gm and 250 gm and their age ranged between 4 and 5 months old. After acclimatization to the laboratory conditions for one week, every two female rats were kept with one male rat and left overnight in a separate cage to allow mating. Early in the next morning, copulation was confirmed by vaginal smear. The copulation was confirmed in thirty female albino rats. The gestational day zero was defined when spermatozoa were observed in a smear of the vaginal contents.

Twenty-four pregnant rats were selected for the present study and divided into (group I, group II and group III). Each group comprised of eight pregnant rats. Pregabalin was given to group II. Pregabalin and folic acid were given to group III. No medications were given to group I. The Pregabalin dose was 80 mg/kg B.w /day (about 1ml of the produced suspension),⁷ and the Folic acid dose was 400 µg/kg B.w /day (about 4 ml of the produced suspension).⁸ The medications were given by oral gavage, once daily, from gestational day one till birth.

30 offspring born to the three experimental groups, were sacrificed at two and four weeks after birth (5 offspring from each group for each age), therefore two subgroups for each group were formed as follow: Subgroup I-A of 5 rats; sacrificed at 2 weeks old, Subgroup I-B of 5 rats; sacrificed at 4 weeks old, Subgroup II-A of 5 rats; sacrificed at 2 weeks old, Subgroup II-B of 5 rats; sacrificed at 4 weeks old, Subgroup III-A of 5 rats; sacrificed at 2 weeks old and Subgroup III-B of 5 rats; sacrificed at 4 weeks old. The cerebellum was carefully dissected out from the skull of each rat and prepared for examination by the light and electron microscopes.

This study was carried out in accordance with the NIH recommendations and guidelines for the use and care of laboratory animals with approval from the ethics committee of the Faculty of Medicine, Al-Azhar University, Cairo, Egypt.

For examination by the light microscope, samples from the cerebellum were taken from each hemisphere and cut into small pieces (about 2-4 mm³), put in Bouin's solution for fixation, and then proceeded to be embedded in the paraffin wax. Sections of 5-micron thickness were obtained for staining with hematoxylin and eosin (Hx & E),⁹ also; some of these sections were used for glial fibrillary acidic protein (GFAP) immune-reaction.¹⁰

For examination by the electron microscope, small pieces (about 1 mm³) were obtained from the cortices of each cerebellar hemisphere, put in 2.5% glutaraldehyde for fixation, and then prepared for embedding in epon resin. Semithin sections of 1µm thickness were obtained and stained with toluidine blue. The ultrathin sections of (50 nm) thickness were obtained and mounted on grids of copper to be ready for staining with lead citrate and uranyl acetate.¹⁰ The examination of the sections was carried out by using a transmission electron microscope. Photomicrographs were taken under different magnifications to detect the ultrastructure of the cerebellar cortex.

Histomorphometric measurements were conducted on Hx & E and GFAP stained sections in different random fields with a fixed area (about 4 X 104 µm²). The density of Purkinje cells and the percentage of the area of GFAP immune reaction were measured in magnification X400. The measurements were obtained in non-overlapping 10 fields for each specimen by using an image analyzer computer system, V4.8, Leica LAS, Switzerland.

The collected data by the histomorphometric measurements, from the three experimental groups, was first represented as means with standard deviations (\pm SD), and then statistically analyzed by using SPSS 22 program. A comparison between the experimental groups was carried out by using ANOVA test. A comparison of significance was made between the subgroups of group I and the other subgroups. P-value was considered significant when its value \leq 0.05 and was considered highly significant when its value \leq 0.001.

RESULTS

Results of the light microscope examination: Histological evaluation of Hx & E stained sections of subgroups I-A and I-B showed the normal cerebellar cortex morphology. The layer of Purkinje cells was observed containing large oval cells arranged in on row between the molecular and the internal granular layers. Their nuclei appeared large, vesicular in the pale cytoplasm. The molecular layer was observed with a small number of the basket and stellate cells. The internal granular layer was observed containing granule cells. These cells were small and deeply stained. In subgroup I-A, the external granular layer comprised many layers of small darkly stained cells. These cells were closely packed. In subgroup I-B, the external granular layer comprised one or two layers of cells (Figures 1a, 1b). Degenerative changes were observed in the cerebellar cortices of the offspring of group II (subgroups II-A, II-B). These changes included depletion of Purkinje cells that appeared deformed, shrunk, and surrounded by vacuolated spaces. The external granular layer displayed deeply

stained pyknotic cells. Closely packed cells with small size and pyknotic changes were seen in the internal granular layer. Some spaces between these cells were seen congested. Basket and stellate cells were observed within the molecular layer with pyknotic changes; also, some vacuolated areas were seen in this layer. There was a hemorrhage between the folia of the cerebellum (Figures 1c, 1d).

Improvement in the morphology of the cerebellar cortices of subgroups III-A and III-B was noticed. The oval-shaped Purkinje cells were observed again as in group I with vesicular nuclei in granular cytoplasm. The molecular layer was observed with a scattered basket and stellate cells, and with minimum vacuolated areas. Besides, normal granule cells were observed in the internal granular layer. (Figures 1e, 1f).

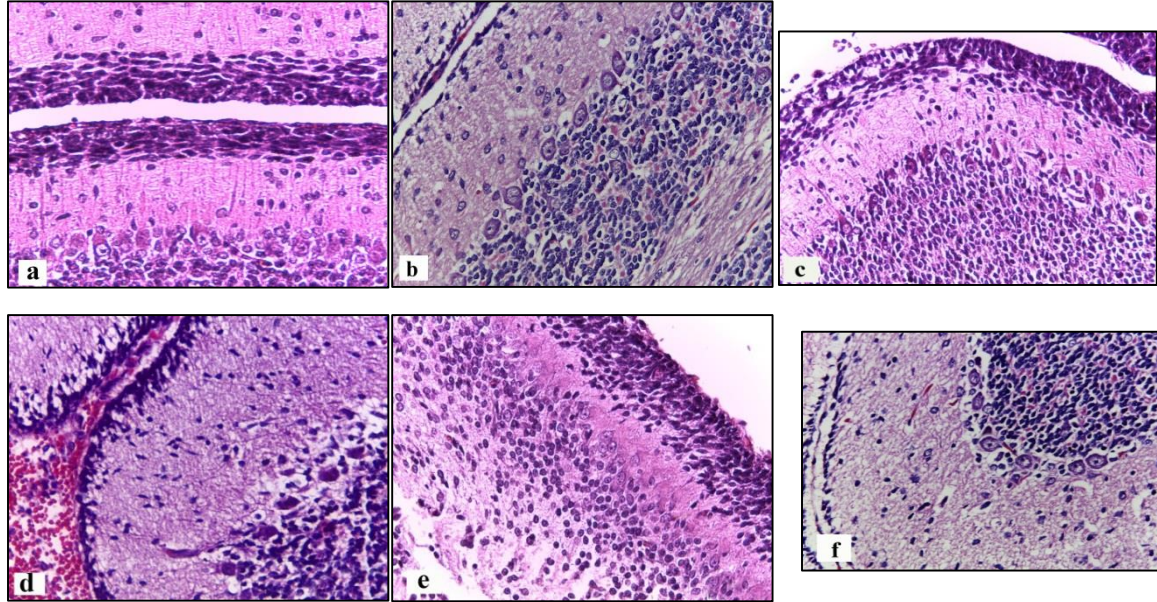


Fig. 1: Photomicrographs of Hematoxylin and eosin-stained sections of the cerebellar cortex of albino rat. a = 2 weeks old rat (subgroup I-A), b = 4 weeks old rat (subgroup I-B), c = 2 weeks old rat (subgroup II-A), d = 4 weeks old rat (subgroup II-B), e = 2 weeks old rat (subgroup III-A), f = 4 weeks old rat (subgroup III-B) (all photomicrographs with magnification X 400).

Results of GFAP immune reaction: Sections of subgroups I-A and I-B showed the weak immune reaction of GFAP in the form of small areas of brown colure (Figures 2a, 2b). Sections of subgroups II-A

and II-B showed the strong immune reaction of GFAP indicating large areas of gliosis due to astrocyte proliferation (Figures 2c, 2d). Sections of subgroups III-A and III-B showed the moderate immune reaction of GFAP (Figures 2e, 2f).

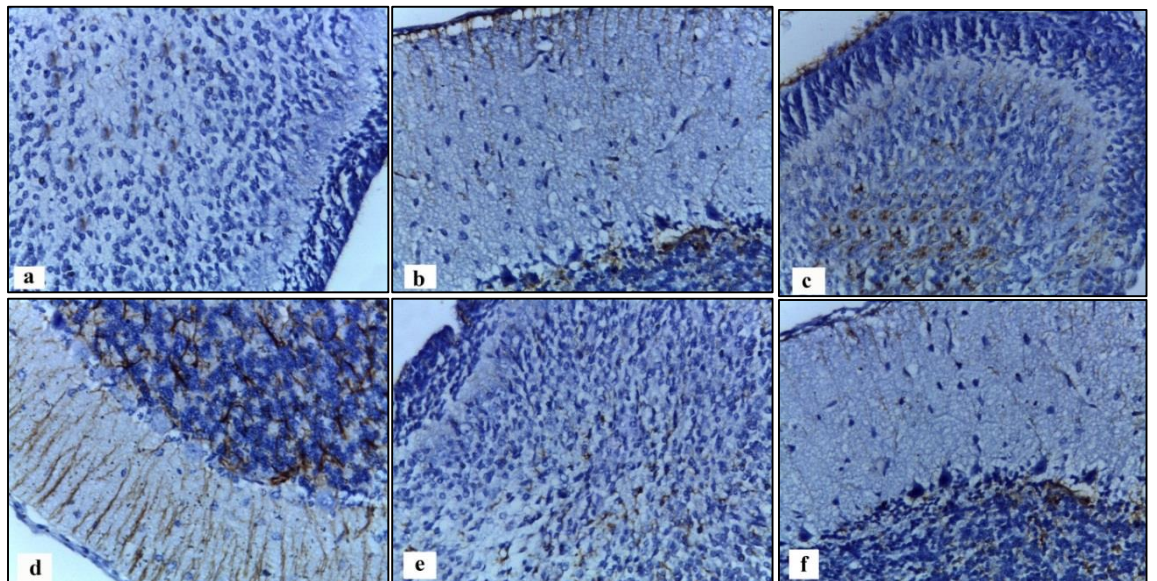


Fig. 2: Photomicrographs of sections of GFAP immune reaction of the cerebellar cortex of albino rat. a = 2 weeks old rat (subgroup I-A), b = 4 weeks old rat (subgroup I-B), c = 2 weeks old rat (subgroup II-A), d = 4 weeks old rat subgroup II-B), e = 2 weeks old rat (subgroup III-A), f = 4 weeks old rat (subgroup III B) (all photomicrographs with magnification X 400).

Results of the electron microscope: Examination of the cerebellar cortex of subgroups I-A and I-B, showed normal Purkinje cells with intact cell membranes and normal axon hillocks. The nucleus was seen normal with dispersed chromatin and clear nucleolus. A large number of mitochondria were observed in the cytoplasm. There were a large number of axons, some were myelinated and some were unmyelinated. The axons were seen contained many neurofilaments and mitochondria. The astrocyte nucleus was seen with the intact nuclear membrane and regularly distributed euchromatin. There was a microglial cell with an oval indented nucleus (Figures 3a, 3b). Examination of the cerebellar cortex of subgroups II-A and II-B showed Purkinje cells surrounded by irregular cell membranes and containing shrunken nuclei with small eccentric nucleoli. The nuclear envelopes of these nuclei were irregular and the chromatin material was rarefied.

Their cytoplasm contained many vacuolations, many degenerated mitochondria, and rough endoplasmic reticula that were dilated. Also, many degenerated axons were completely vacuolated. A degenerate microglial cell was seen surrounded by degenerated axons. The granule cells appeared degenerated with abnormal nuclei and clumping of their chromatin material (Figures 3c, 3d). Examination of the cerebellar cortex of subgroups III-A and III-B showed intact Purkinje cells. Their nuclei were noticed normal and surrounded by a regular, intact nuclear envelope. The cytoplasm appeared nearly normal containing many mitochondria. A microglial cell was seen containing dense cytoplasm and an irregular nucleus. There were many normal granule cells with normal nuclei and condensed chromatin material. There were many normal axons and few degenerated axons, which were completely vacuolated (Figures 3e, 3f).

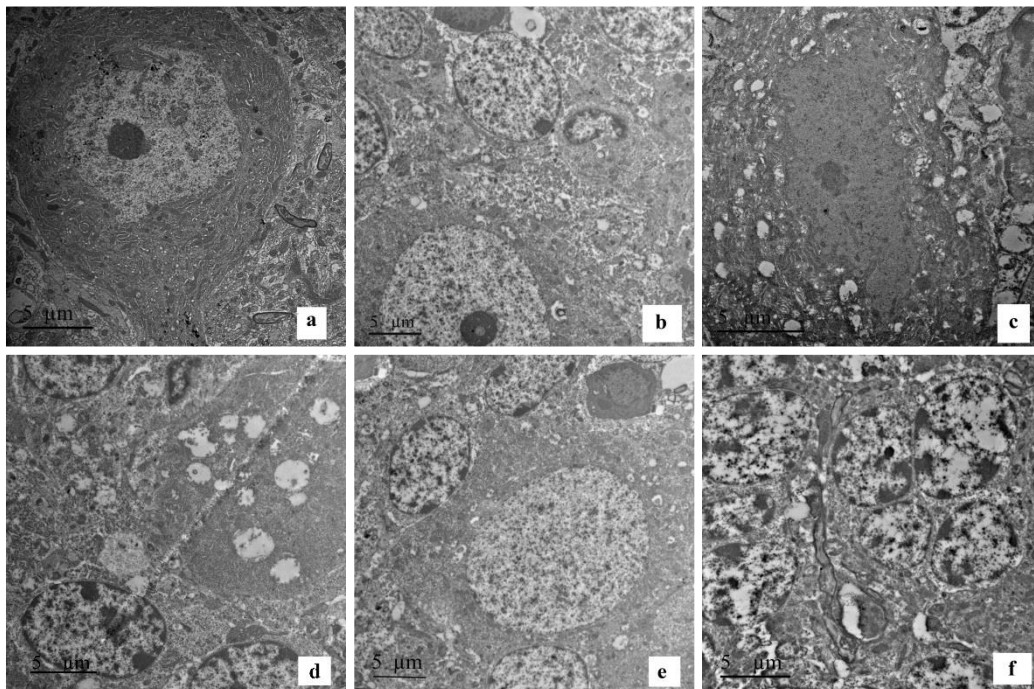


Fig. 3: Electronmicrographs of the cerebellar cortex of albino rat. a = 2weeks old rat (subgroup I-A) (TEM X 4000), b = 4weeks old rat (subgroup I-B) (TEM X 3000), c = 2 weeks old rat (subgroup II-A) (TEM X 5000), d = 4 weeks old rat (subgroup II-B) (TEM X 4000), e = 2 weeks old rat (subgroup III-A) (TEM X 3000), f = 4 weeks old rat (subgroup III-B) (TEM X 4000).

Histomorphometric results: there was a highly significant decrease in the mean density of Purkinje cells in subgroups II-A and II-B when compared with the same subgroups of group I, while a non-significant

decrease was reported in the mean density of Purkinje cells in subgroups III-A and III-B when compared with the same subgroups of group I (Table I).

Subgroups	I-A	I-B	II-A	II-B	III-A	III-B
Mean ±SD	43.16 ±14.8	49.24 ±28.1	28.22 ±22.2	22.22 ±14.4	35.46 ±19.2	38.24 ±19.6
P-value			≤ 0.001 **	≤ 0.001 **		

Table 1: Showing the mean density of the Purkinje cells of the cerebellar cortices of all experimental subgroups. (**) Indicate a highly significant difference.

A high significant increase in the area percentage of GFAP immune reaction was detected in subgroups III-A and III-B when compared with the same subgroups of group I. Meanwhile, a significant increase in the

area percentage of GFAP immune reaction was detected in subgroups III-A and III-B when compared with the same subgroups of group I (Table II).

subgroups	I-A	I-B	II-A	II-B	III-A	III-B
Mean	0.26 %	0.56 %	3.6%	5.52%	1.66%	1.90%
±SD	± 0.11	±0.22	± 2.3	±2.62	±0.32	±0.25
P-value			≤ 0.001 **	≤ 0.001 **	≤ 0.03 *	≤ 0.03 *

Table 2: The mean area percentage of GFAP immune reaction in the cerebellar cortices of all experimental subgroups. (**) Indicate a high significant difference (*) Indicates a significant difference.

DISCUSSION

The present study demonstrated that the external granular layer of 2 weeks old rat, born to controlled mothers, was formed of many layers of small cells that were packed together with deeply stained nuclei. At the age of 4 weeks, the external granular layer was seen forming a rim on the outer surface of the folium. This may be explained by the migration of the cells from the external granular layer towards the internal granular layer through the molecular and the Purkinje layers.¹¹

The present work revealed that prenatal exposure to pregabalin markedly affected the postnatal structure and morphology of the cerebellar cortex of offspring. In the present study, the toxicity of pregabalin was mostly manifested in the Purkinje cell layer; which in turn was reflected on the morphological structure of all layers of the cerebellar cortex. These findings were in agreement with Yadav et al.⁴ who found that prenatal administration of pregabalin disrupted the architecture and the linear arrangement of the cells in the Purkinje layer. The ultrastructural changes of Purkinje cells of offspring born to pregabalin treated mothers in the current study confirmed the histological changes noticed by the light microscopic examination; in the form of nuclear changes, irregular cell membranes. These nuclear changes of the Purkinje cells were further accompanied by abnormalities in the cytoplasm, which displayed dilatation of the endoplasmic reticulum, vacuolations, and loss of cytoplasmic organelles. Sobaniec,¹² explained that the dark appearance of Purkinje cells was probably due to the apoptosis process because these cells

displayed markedly condensed karyoplasm and cytoplasm. Also, Chavez-Valdez et al.¹³ postulated that the dilation of the endoplasmic reticulum is possible during necrosis.

The present study revealed marked degeneration of the axons, which displayed vacuolations with loss of neurofilaments, and organelles and this might be due to toxic effects caused by pregabalin on the cerebellum. This was in agreement with Lehning et al.¹⁴ who found that the injured neurons were not able to maintain their distal processes, so they suggested that the degeneration of axons might be a phase of the dying back process of the neuronal injury. Shalaby and Sarhan,¹⁵ attributed the loss of myelin sheath to the damage in the cellular contents such as lipids, DNA, and proteins.

The current study estimated the immunohistochemical expression of GFAP at different postnatal ages and detected statistically significant, strong positive immune reactivity in offspring born to pregabalin treated mothers.

After any injury in the central nervous system, either because of a disease chemical insult, trauma, or genetic disorders, the astrocytes become in a reactive state and responds to this injury by a process called astrogliosis. In the process of astrogliosis, GFAP is rapidly synthesized by astrocyte, so this process can be detected by immunostaining with the GFAP antibody.¹⁶ so, in this study, the astrogliosis could be a result of the toxic effect of pregabalin on neurons of the cerebellum.

Evidence in support of pregabalin induced astrocyte activation has been proposed by Gottfried et al.¹⁷ who declared that astrocytes become reactive during valproic acid treatment being characterized by up-

regulation of GFAP and showed a higher number of processes than the control ones. Moreover, Lee et al.¹⁸ reported an increase in glial fibrillary acidic protein because of prenatal antiepileptic drug exposure.

Pregabalin teratogenicity could be explained by the increase in fetal oxidative stress, as the fetal brain in the rat is more susceptible to increased oxidative stress in comparison to other fetal organs.^{19, 20} Kamel,²¹ reported that pregabalin caused oxidative DNA damage and elevation in some serum biochemical parameters related to the liver and produced oxidative stress in the albino rat.

In this study, the administration of folic acid was effective in decreasing the toxic effect of pregabalin on the cerebellar cortex. This observation was in agreement Yadav et al.⁴ who found that combined administration of folic acid and pregabalin to pregnant mice led to an amelioration of the deleterious effects of pregabalin on the cerebellar cortex of their offspring.

CONCLUSION

From this study, it was concluded that the administration of pregabalin drug to pregnant rats had neurotoxic effects on the developing cerebellar cortex of Rat's Offspring. Besides, it was concluded that the administration of the folic acid with the Pregabalin drug could reduce these neurotoxic effects of the pregabalin on the development of the cerebellar cortex. So, it is recommended to give folic acid supplements to pregnant mothers treated with pregabalin to guard against the toxicity of pregabalin on the development of the cerebellar cortex.

REFERENCES

1. Kashif T, Fathima N, Usman N, et al. Women with Epilepsy: Anti-epileptic Drugs and Perinatal Outcomes. *Cureus*. 2019; 11(9): 42-56. doi: 10.7759/cureus.5642.
2. Morano A, Palleria C, Citraro R, et al. Immediate and controlled-release pregabalin for the treatment of epilepsy. *Expert Review of Neurotherapeutics*. 2019; 19 (12): 1167-77. doi: 10.1080/14737175.2019.
3. Menachem E. Pregabalin pharmacology and its relevance to clinical practice. *Epilepsia*. 2004; 45 (6): 13-18. doi: org/10.1111/j.0013-9580.2004.455003.x.
4. Yadav P, Shrestha S, Kushwaha R, et al. Effect of Folic Acid in Prenatal Pregabalin-Induced Cerebellar Changes in the Swiss Albino Mice. *International Journal of Therapeutic Applications*. 2018; 35: 19-27.
5. Salih L, Al-mahdawi A, and Al-Salihi A. Teratological effect of pregabalin drug on the prenatal development of the cerebellum in the albino rat. *J. of Recent Scientific Research*. 2014; 5 (7): 1381-85.
6. Kalhan C. and Marczewski E. Methionine, homocysteine, one-carbon metabolism, and fetal growth, *Rev. in Endocr. Metabol. Dis.* 2012; 13: 109-19. doi: org/10.1007/s11154-012-9215-7.
7. Etemad L, Jafarian A, and Moallem A. Pathogenesis of pregabalin-induced limb defects in mouse embryos. *Journal of Pharmacy & Pharmaceutical Sciences*. 2015; 18(5): 882-9. doi: 10.18433/J3PP5Z.
8. Wilson D, Johnson A, Wyatt P, et al. Pre-conceptional vitamin/folic acid supplementation. the use of folic acid in combination with a multivitamin supplement for the prevention of neural tube defects and other congenital anomalies. *J Obs Gyn Can.* 2007; 29(12): 1003-13. doi: 10.1016/S1701-2163(16)32685-8.
9. Suvarna S, Layton C, and Bancroft D. Bancroft's theory and practice of histological techniques. 8th edition. E-Book. Elsevier Health Sciences; 2018. pp. 172-98.
10. Youssef S, Abd-El- Aty A, Mossalam M. et al. Effects of prenatal phenytoin toxicity on the expression of glial fibrillary acidic protein (GFAP) in the developing rat cerebellum. *Journal of American Science*. 2011; 7(8):139-52.
11. Bénard M, Lebon A, Komuro H., et al. Ex Vivo Imaging of Postnatal Cerebellar Granule Cell Migration Using Confocal Microscopy. *J. Vis. Exp.* 2015; (99): 1-8. doi: 10.3791/52810.
12. Sobaniec-Lotowska M. Ultrastructure of Purkinje cell perikarya and their dendritic processes in the rat cerebellar cortex in experimental encephalopathy induced by chronic application of valproate. *Int. J. Exp. Pathol.* 2001; 82 (6): 337-48. doi:10.1046/j.1365-2613.2001.00206.x.
13. Chavez-Valdez R, Flock D, Martin J. et al. Endoplasmic Reticulum pathology and stress response in neurons precedes programmed necrosis after neonatal hypoxia-ischemia. *Int. J. Dev. Neurosci.* 2017; 48: 58- 70. doi: 10.1016/j.ijdevneu.2015.11.007.
14. Lehning J, Balaban C, Ross J. et al. Acrylamide neuropathy: I. Spatiotemporal characteristics of nerve cell damage in rat cerebellum. *Neurotoxicol.* 2012; 23(3): 397-414. doi:10.1016/s0161-813x(02)00083-9.
15. Shalaby M and Sarhan N. Light and Electron Microscopic Study on the Effect of Valproic Acid on Cerebellar Cortex of Adult Male Albino Rat and The Possible Protective Effect of L-Carnitine. *Egy. J. Histol.* 2008; 31: 256 - 65.
16. Elsayy M, Abdelmalik W, and Habib K. Effect of Terbutaline Intravenous Injection Versus Subcutaneous Pump in the late Gestational days of Pregnant Albino Rat on the Developing Cerebellar Cortex of Their Offspring. *Egyptian Journal of*

- Anatomy*. 2018; 36(1): 123-38. doi: 10.21608/EJANA.2019.32647.
17. Gottfried C, Bambini-Junior V, Baronio D. et al. Valproic acid in autism spectrum disorder: from an environmental risk factor to a reliable animal model. *Recent Advances in Autism Spectrum Disorders*. 2013; 1: 144- 162. doi: [10.5772/54824](https://doi.org/10.5772/54824).
 18. Lee H, Dreyfus C, and Di Cicco-Bloom E. Valproic acid stimulate the proliferation of glial precursors during cortical gliogenesis in developing rat. *Develop. neurobiol*. 2016; 76(7): 780 -98. doi: 10.1016/j.gpb.2016.09.002.
 19. Danielsson B, Danielsson C and Nilsson F. Embryonic cardiac arrhythmia and generation of reactive oxygen species: common teratogenic mechanism for IKr blocking drugs. *Repro. Toxicol*. 2007; 24 (1): 42-56. doi: [10.1016/j.reprotox.2007.04.005](https://doi.org/10.1016/j.reprotox.2007.04.005).
 20. Banji D, Banji O, Abbagoni S. et al. Amelioration of behavioral aberrations and oxidative markers by green tea extract in valproate induced autism in animals. *Brain Res*. 2011; 15 (2): 141-51. doi: 10.1016/j.brainres.2011.06.063.
 21. Kamel A. Study on DNA damage and oxidative stress and some biochemical alterations of long term administration of alpha-2 delta ($\alpha 2-\delta$) ligand pregabalin and the possibility of zingiber officinale in ameliorating these effects in rat. *World J. of Pharmacol. Re*. 2016; 8(6): 1528-45.